



**UNILABMILACENISESIPE**

**NOME DO EVENTO:**

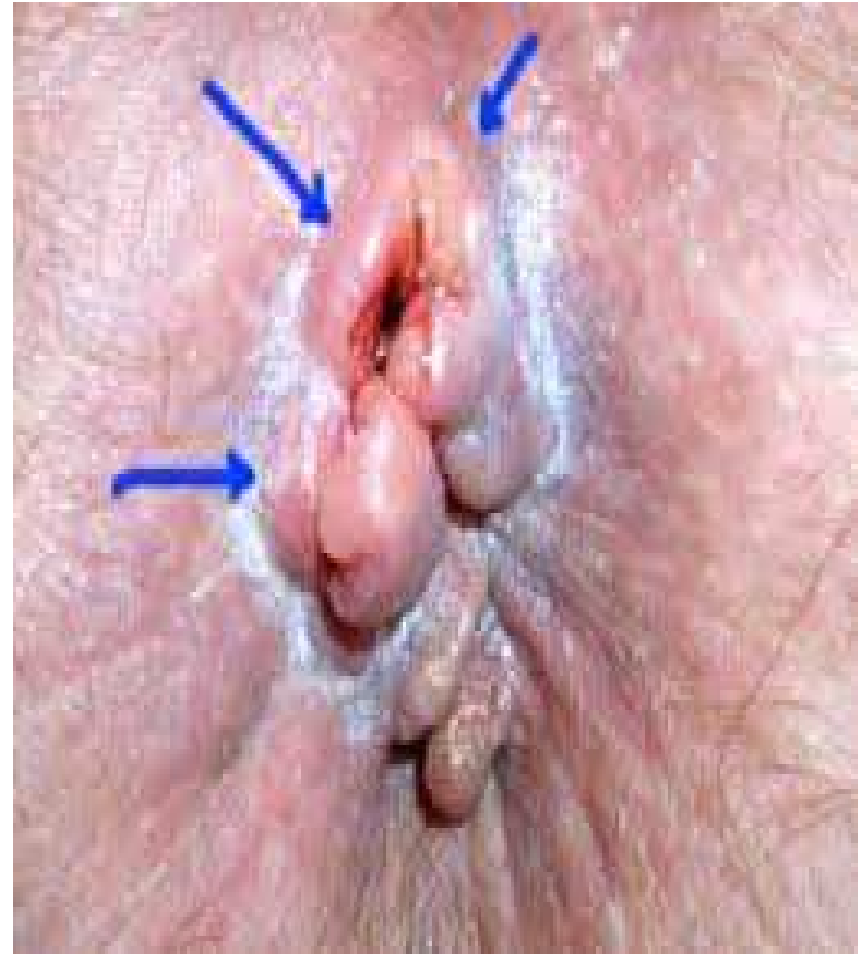**APRESENTAÇÃO  
DE CASOS**

**CITOLOGIA**

**ANAL**

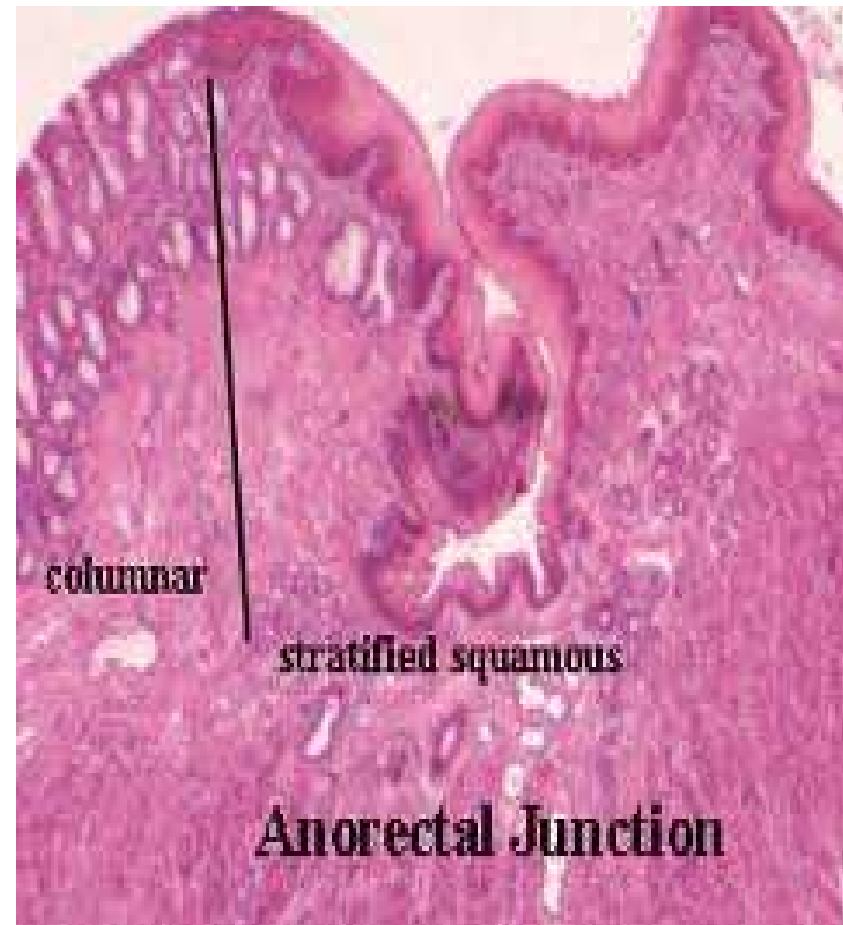
# ***RASTREAMENTO DO CÂNCER ANAL***

- ***Câncer anal \_ 2 a 4%;***
- ***Incidência aumentado;***
- ***Grupos de risco;***
- ***Infecção por HPV.***



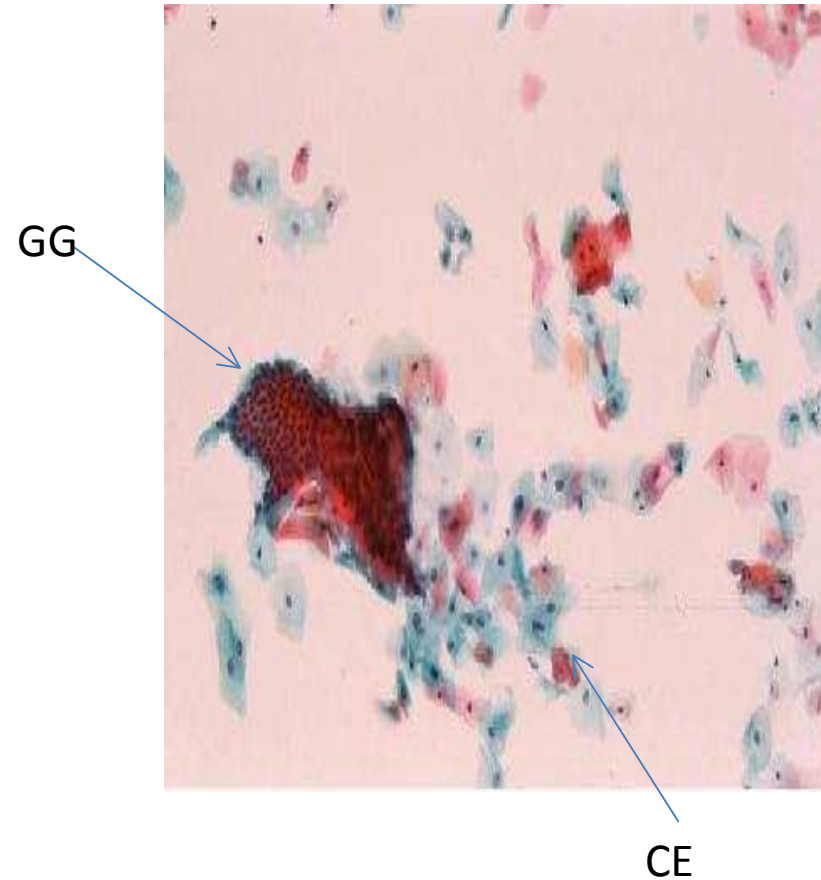
# ***HISTOLOGIA ANAL***

- ***Similaridade histológica;***
- ***Junção escamocolunar anal;***
- ***Princípios do programa de rastreamento para câncer de colo uterino;***



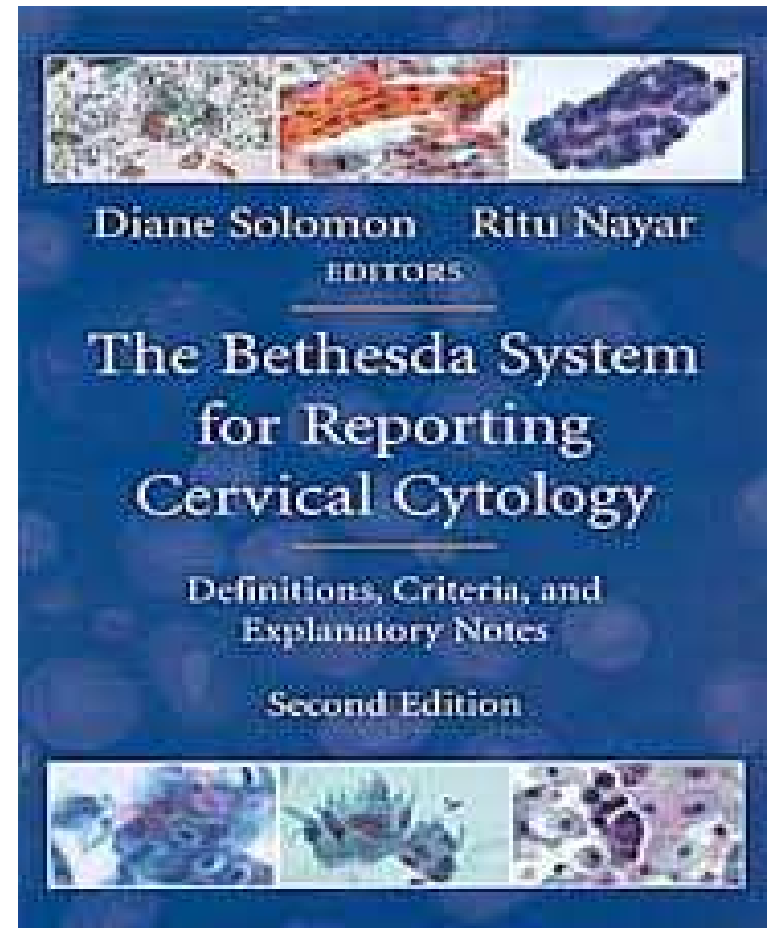
# ***CITOLOGIA ANAL***

- ***Método convencional (6.2%);***
- ***Coleta cega não precisa do anoscopio;***
- ***Baixo custo;***



# ***NOMENCLATURA***

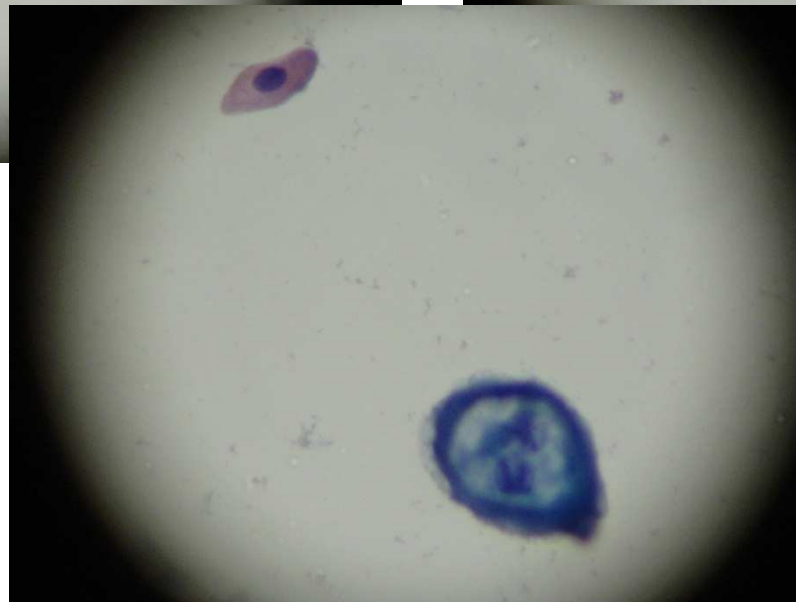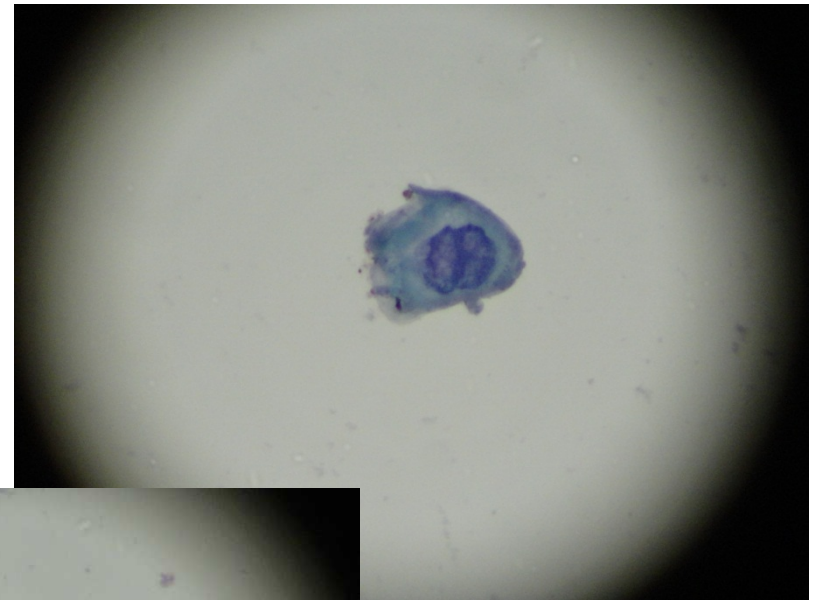
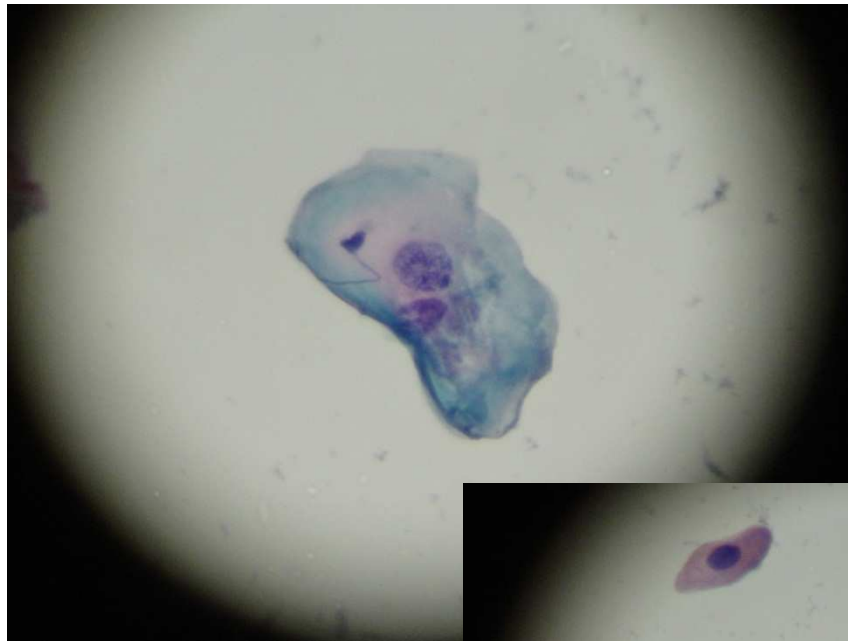
- ***Sistema Bethesda 2001;***
- ***Nomenclatura Brasileira;***
- ***Região anatômica;***
- ***Lesão intraepitelial escamosa anal de baixo e alto grau.***

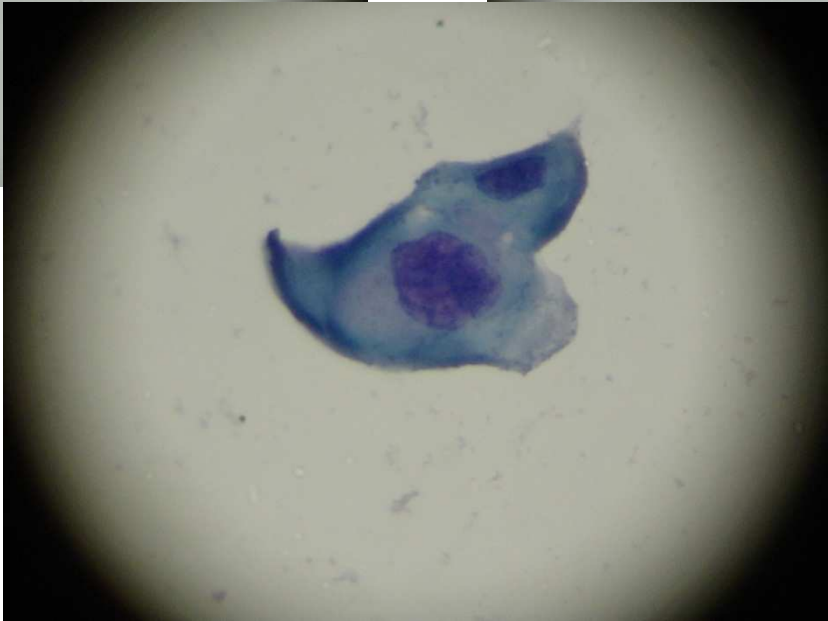
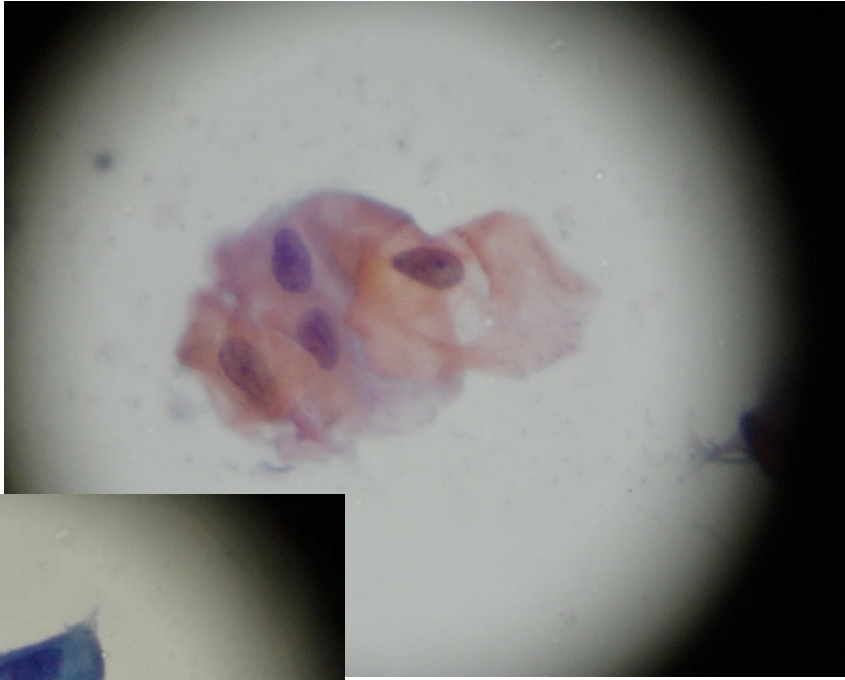
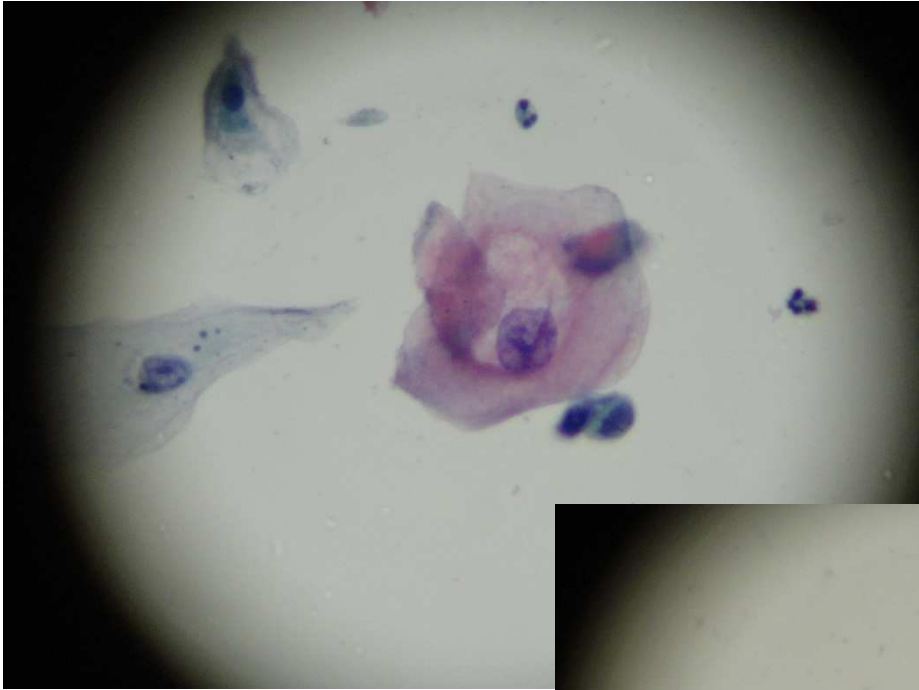


# **CASO 1**

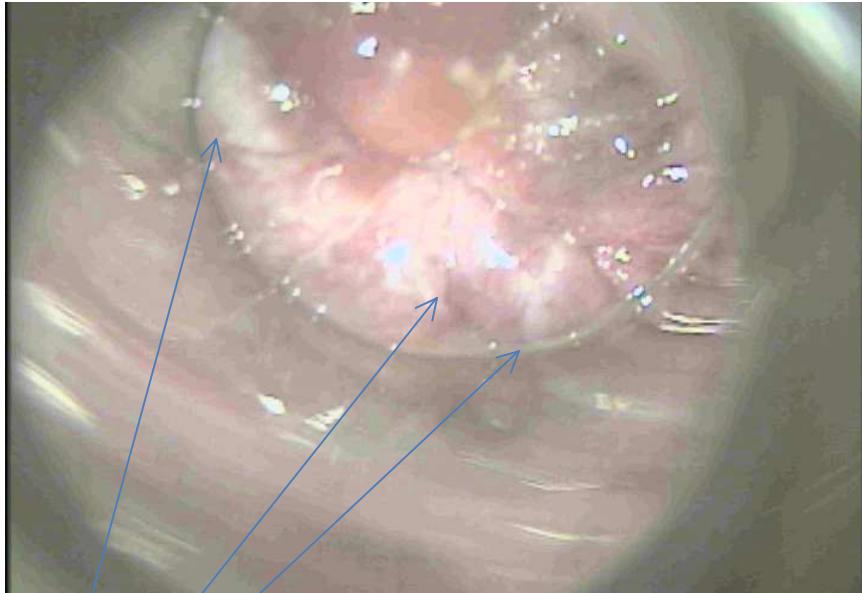
- ***NOME: EM***
- ***REG: 4071346;***
- ***IDADE: 30 anos;***
- ***Diagnóstico histopatológico de NIC 1/ HPV;***
- ***Condiloma vulvar;***
- ***Teste HIV (-)***

# ***CITOLOGIA ANAL***

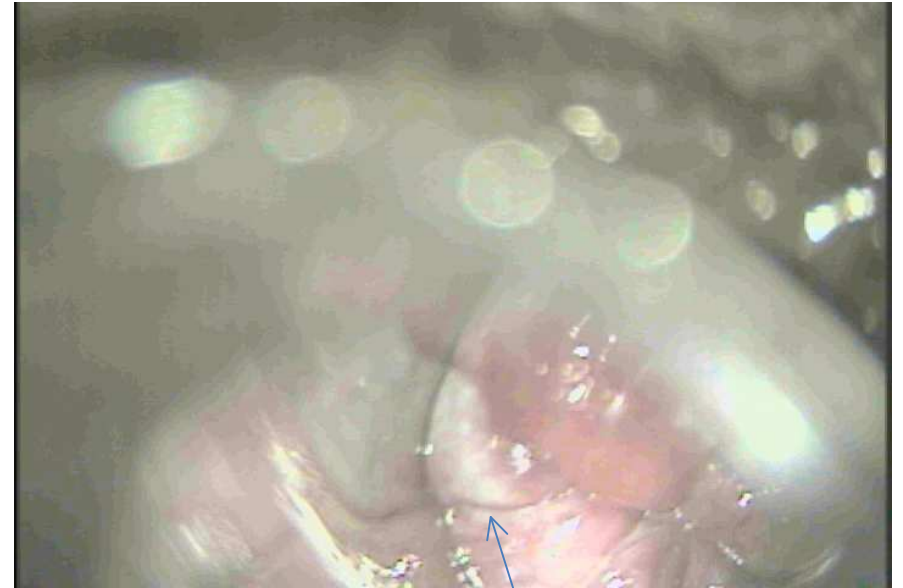




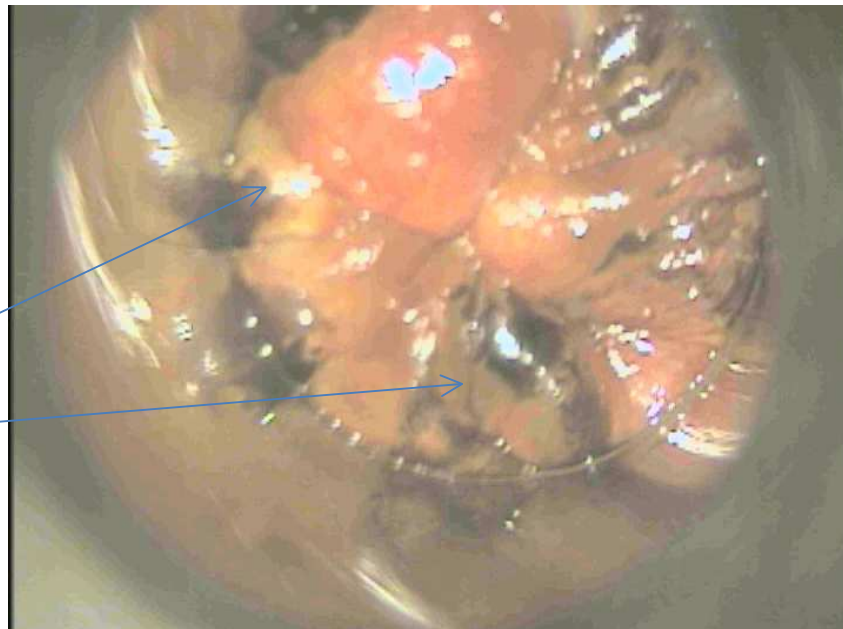




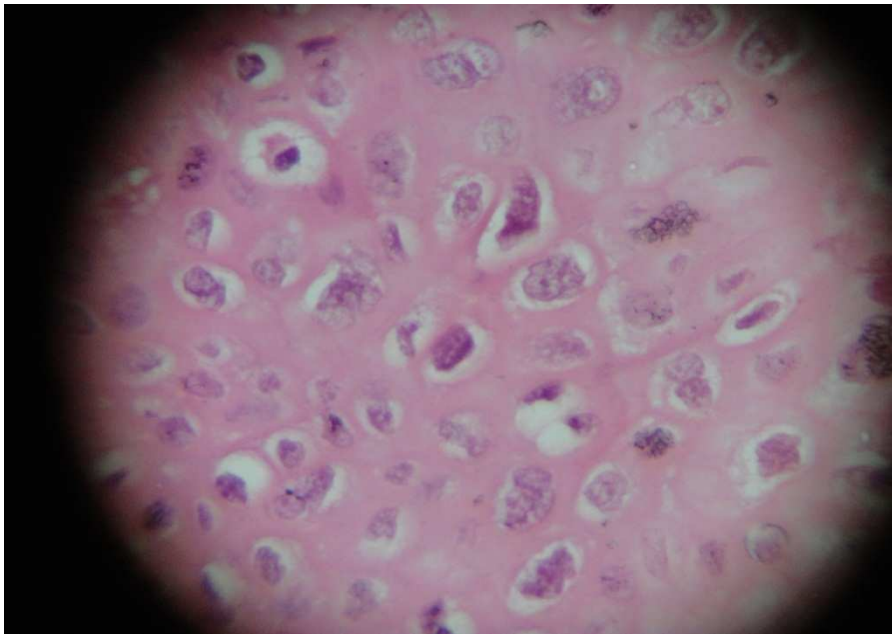
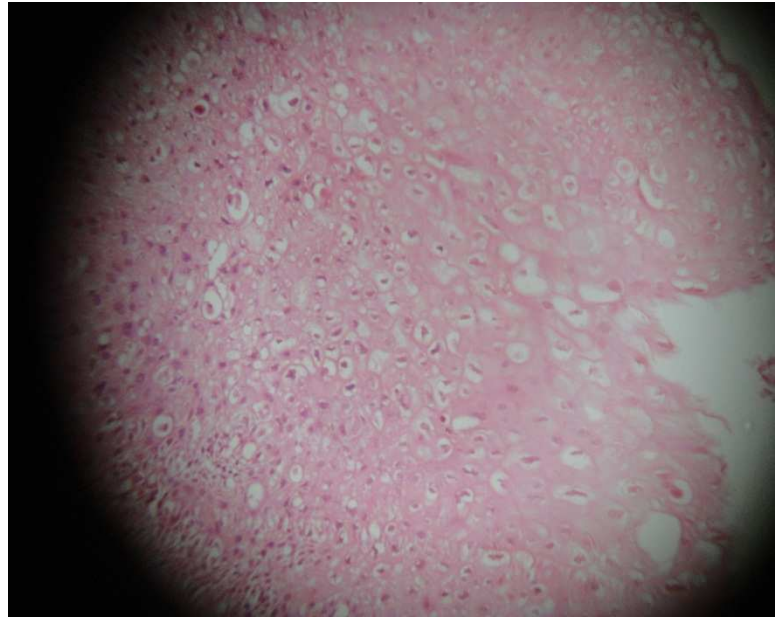
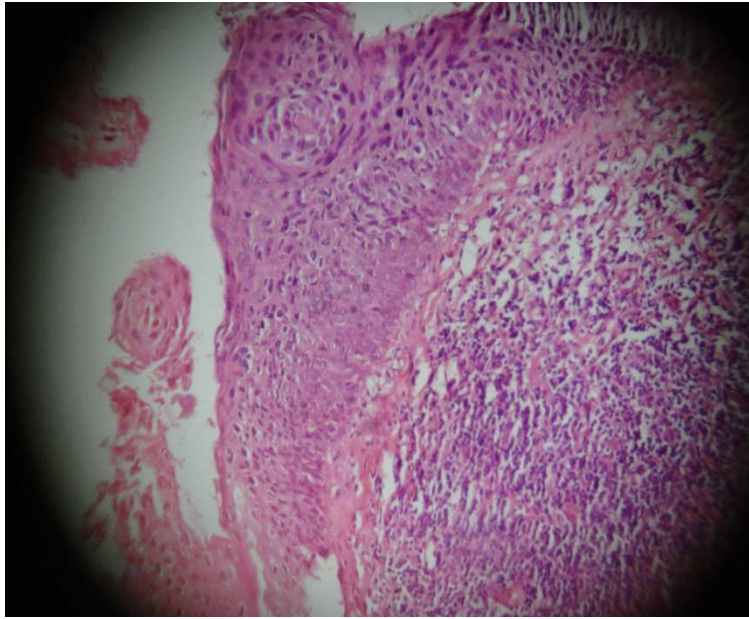
EPITÉLIO  
ACETOBranco



EPITÉLIO  
ACETOBranco  
(MAIOR AUMENTO)



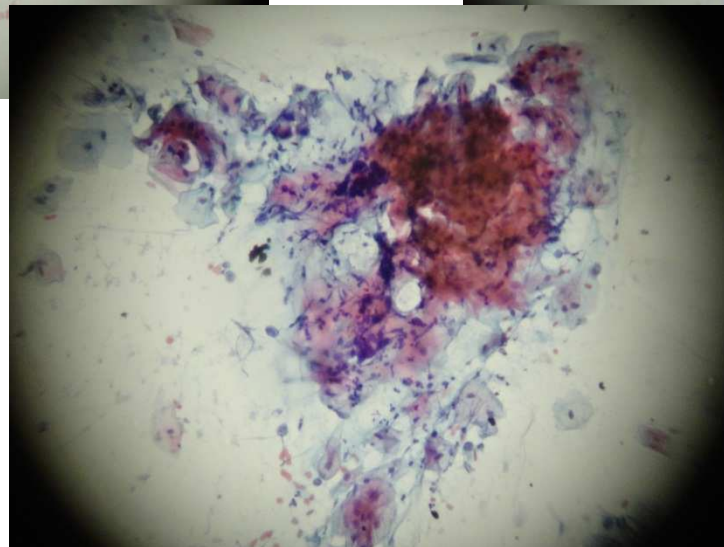
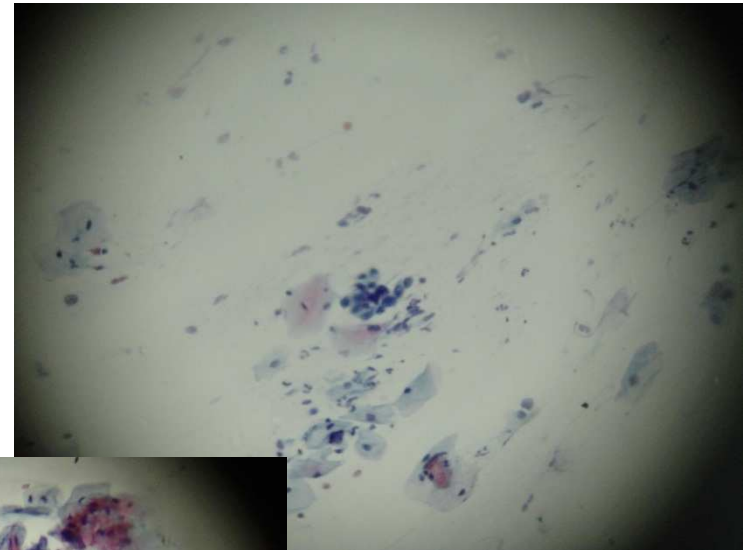
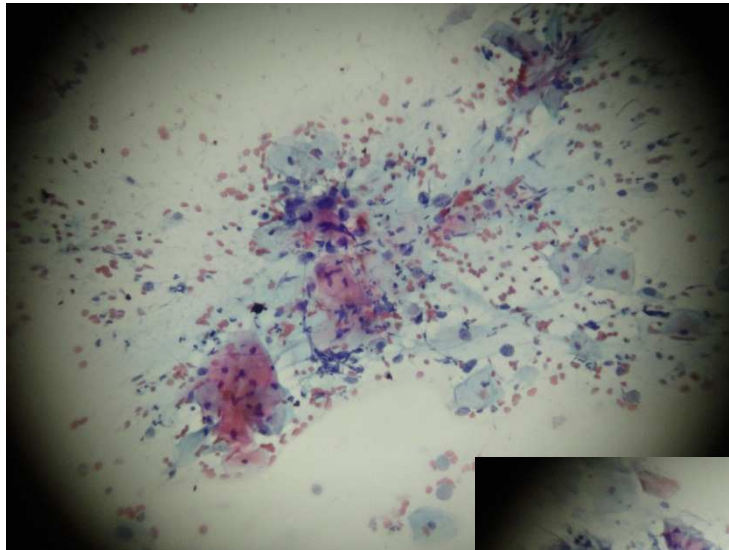
Áreas iodo negativo



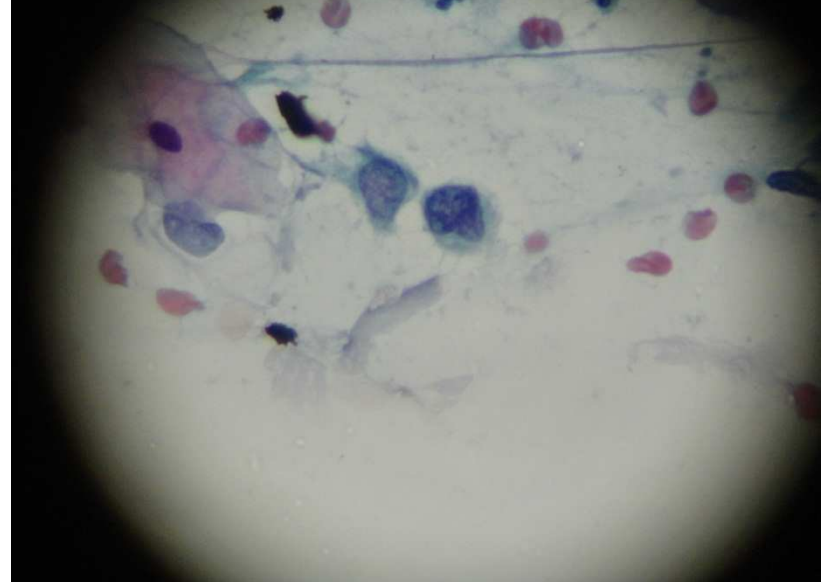
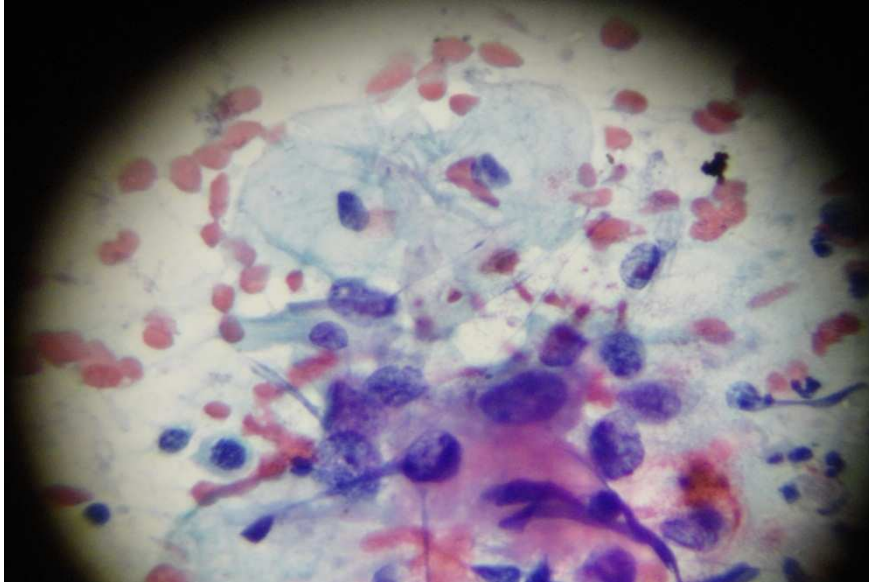
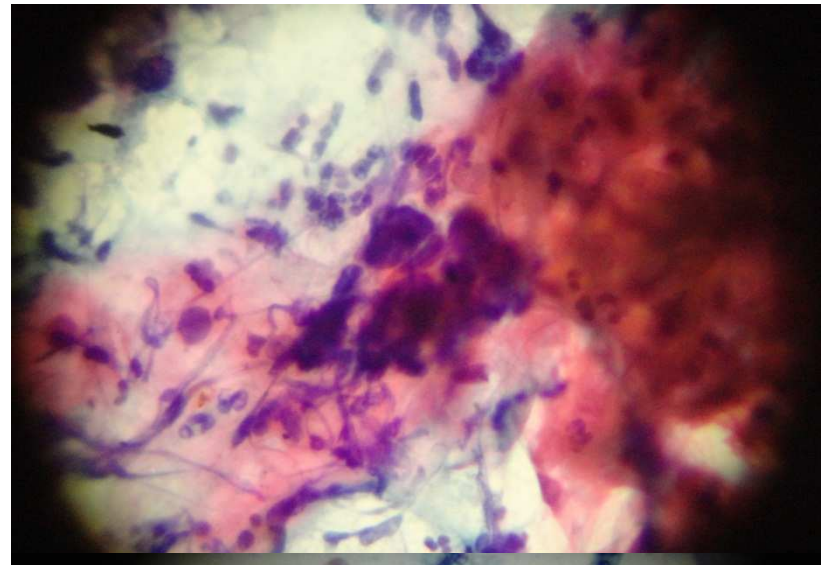
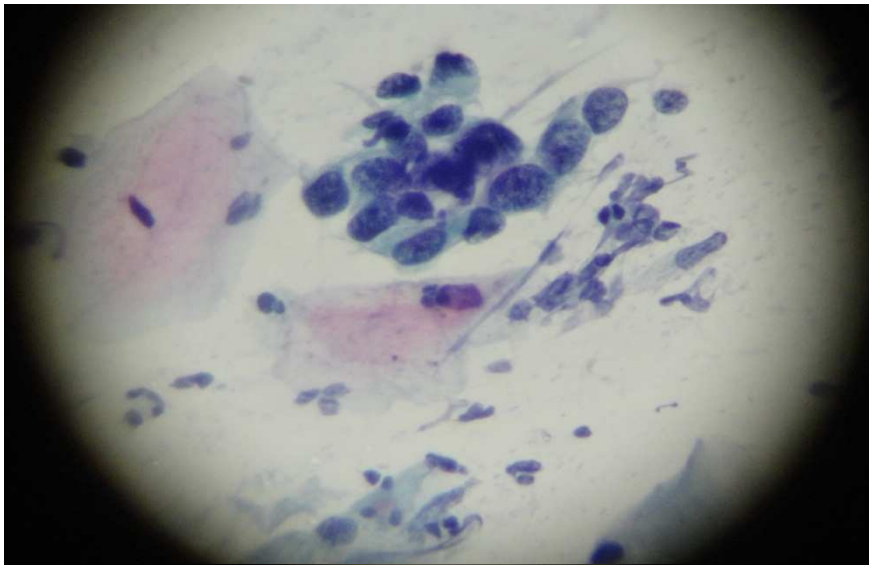
# **CASO 2**

- ***NOME: LRS***
- ***REG: 3324188***
- ***IDADE: 34 anos;***
- ***2009 - Diagnóstico histopatológico de NIC 2/ HPV realizou EZT por CAF.***
- ***Ausência de lesão HPV – induzida em vulva***
- ***Teste HIV (-)***

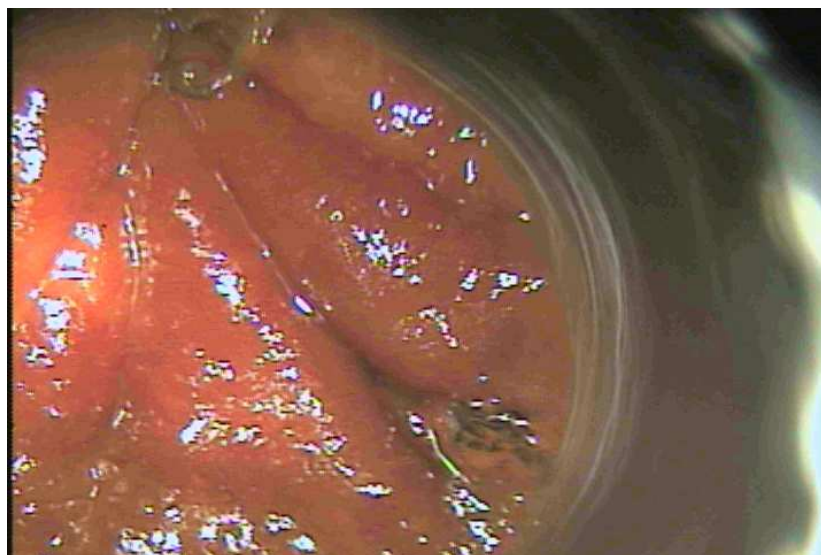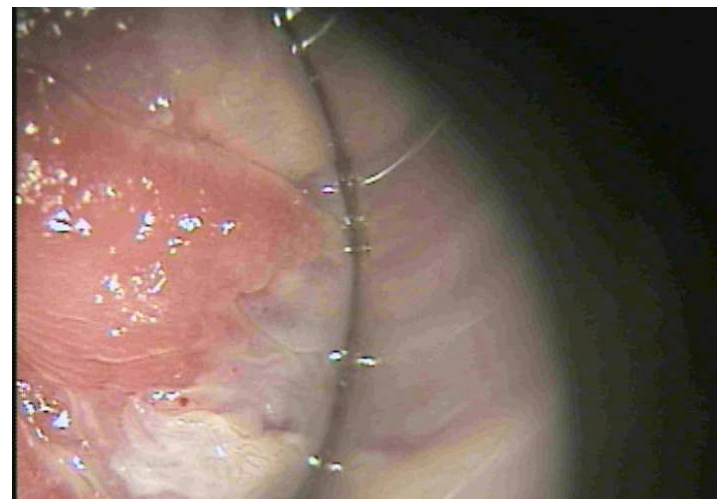
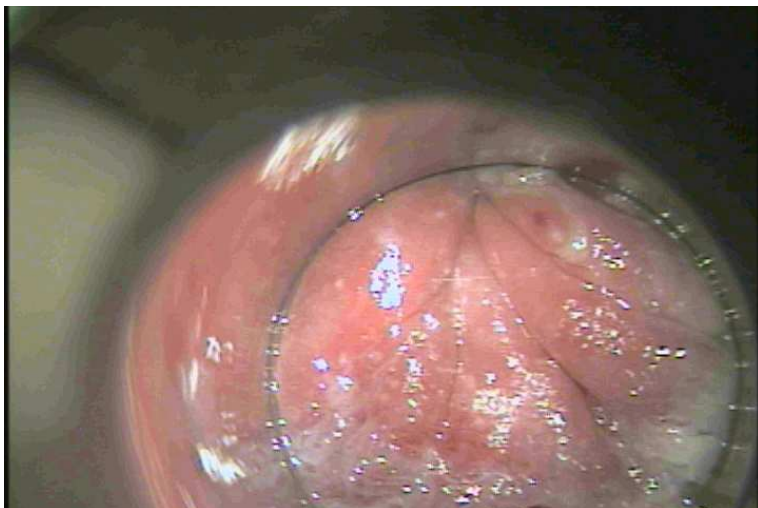
# ***CITOLOGIA ANAL***



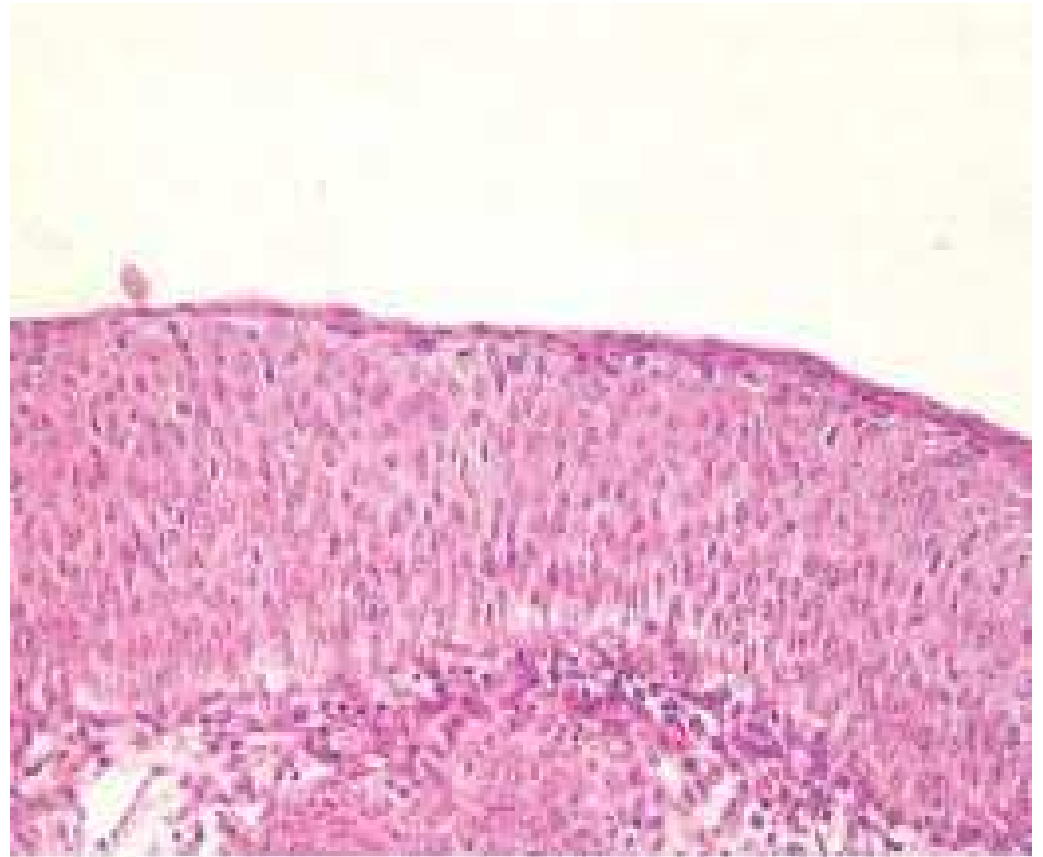
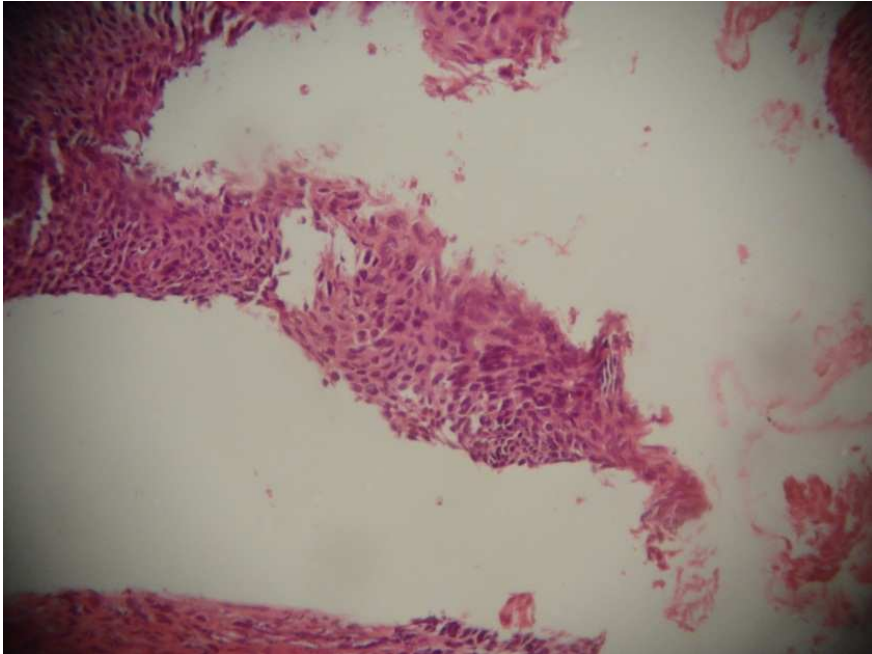
# ***CITOLOGIA ANAL***

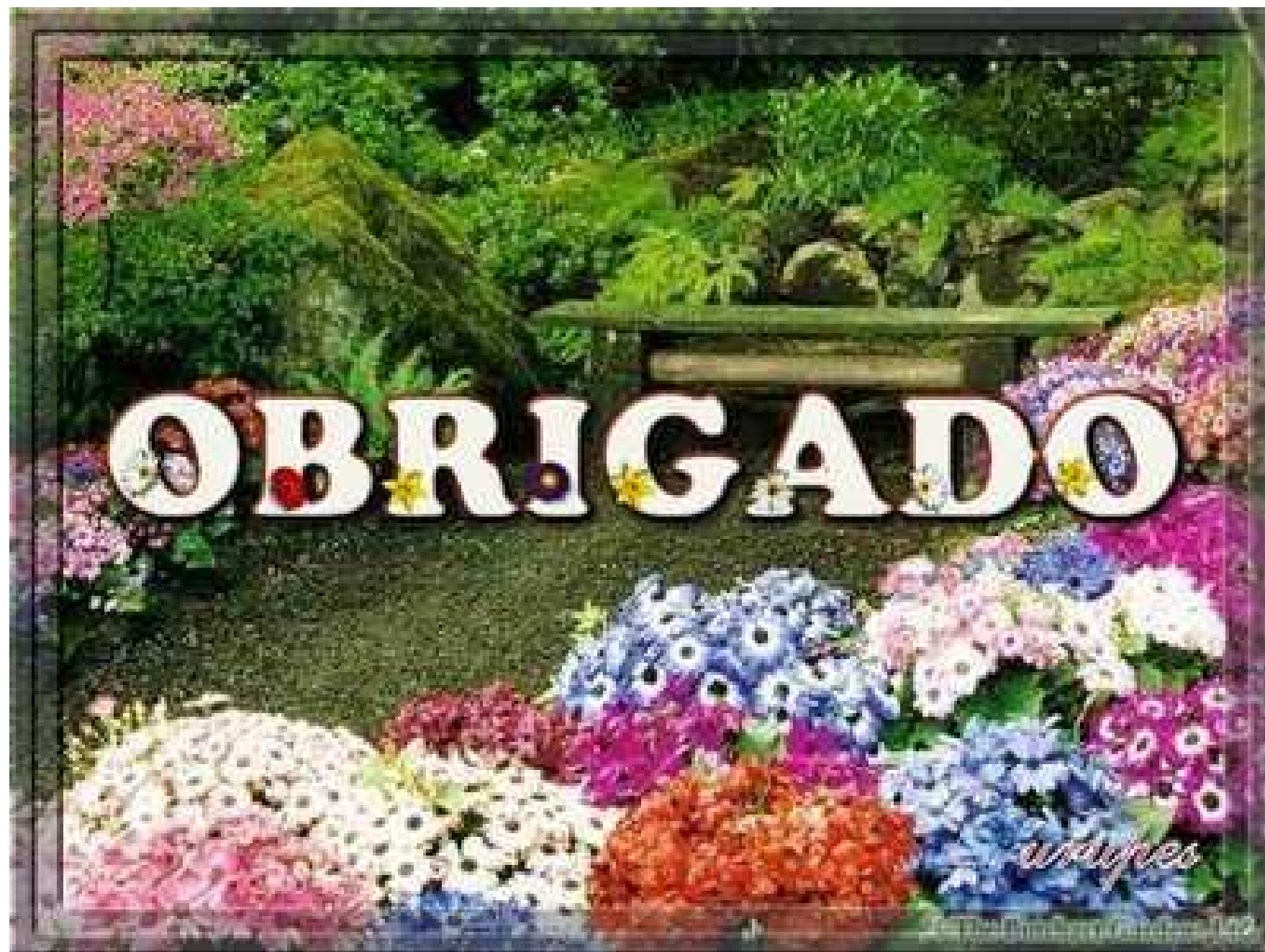

# ***ANUSCOPIA ALTA RESOLUÇÃO***



# ***HISTOPATOLOGIA***





OBRIGADO

W. H. P. 1922