



# 1ª Jornada Internacional de CITOTECNOLOGIA

12 a 14 de Agosto de 2009

## *Casos Clínicos*

*Marina Yoshiê Sakamoto Maeda  
Instituto Adolfo Lutz  
Divisão de Patologia*

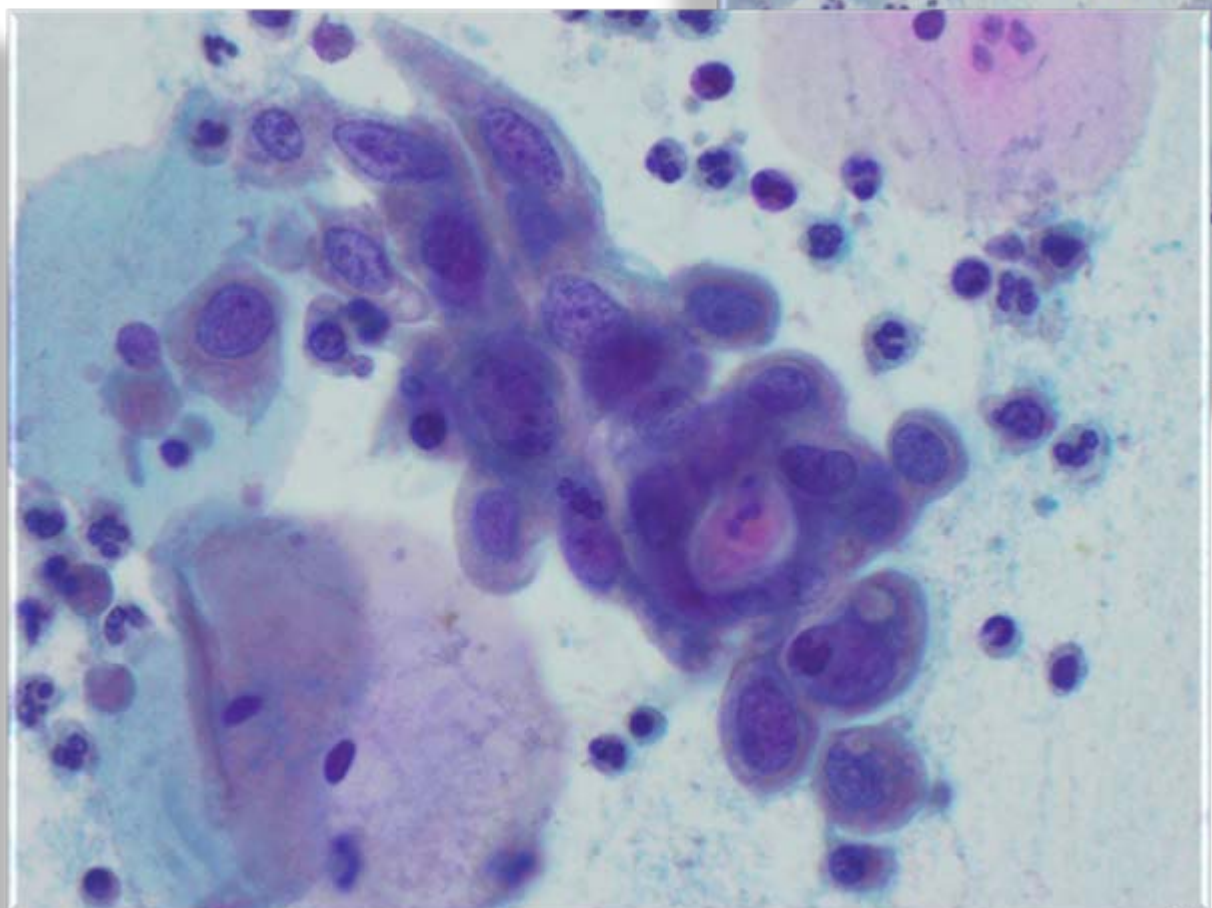
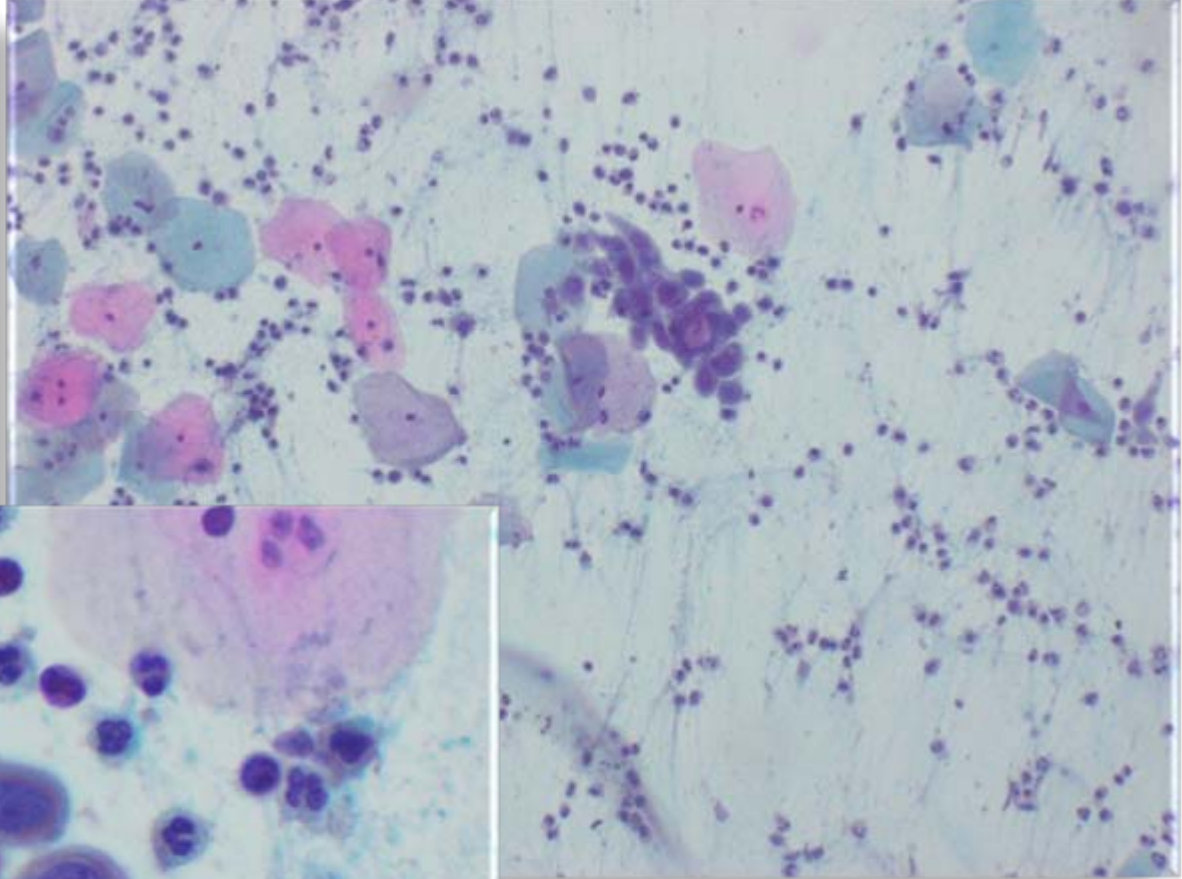
# CASO 1

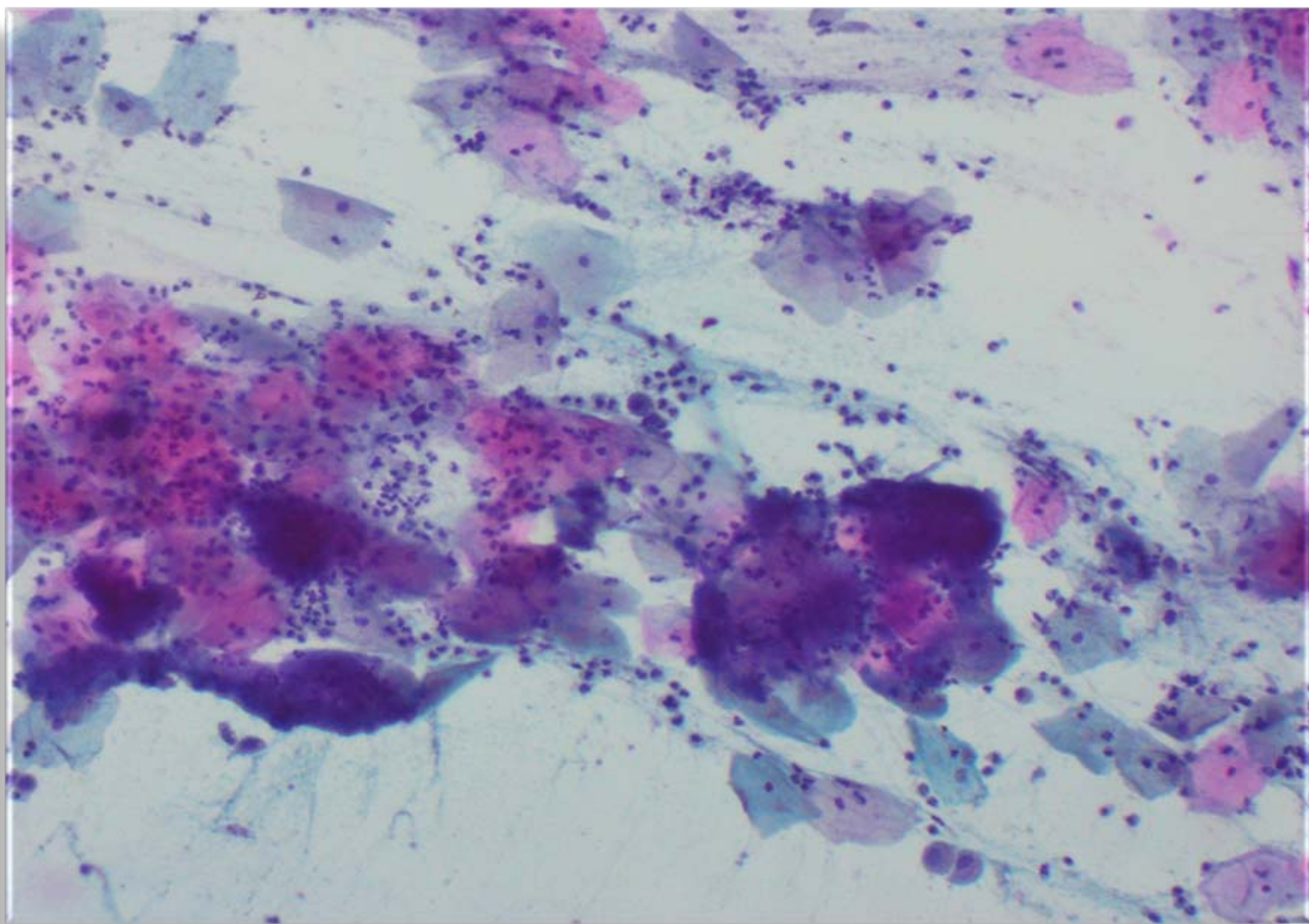
**Paciente de 36 anos**

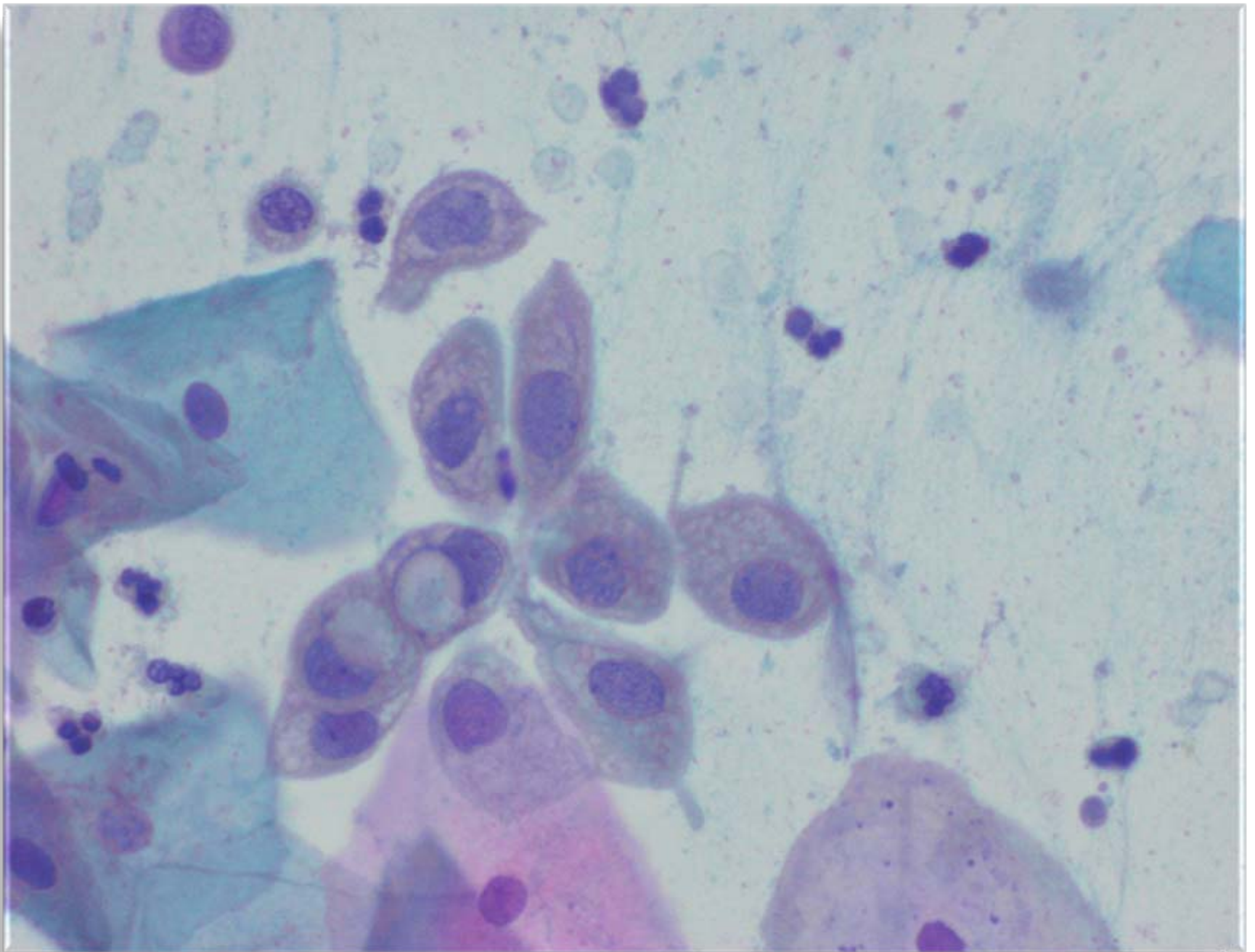
**Usuária de D.I.U.**

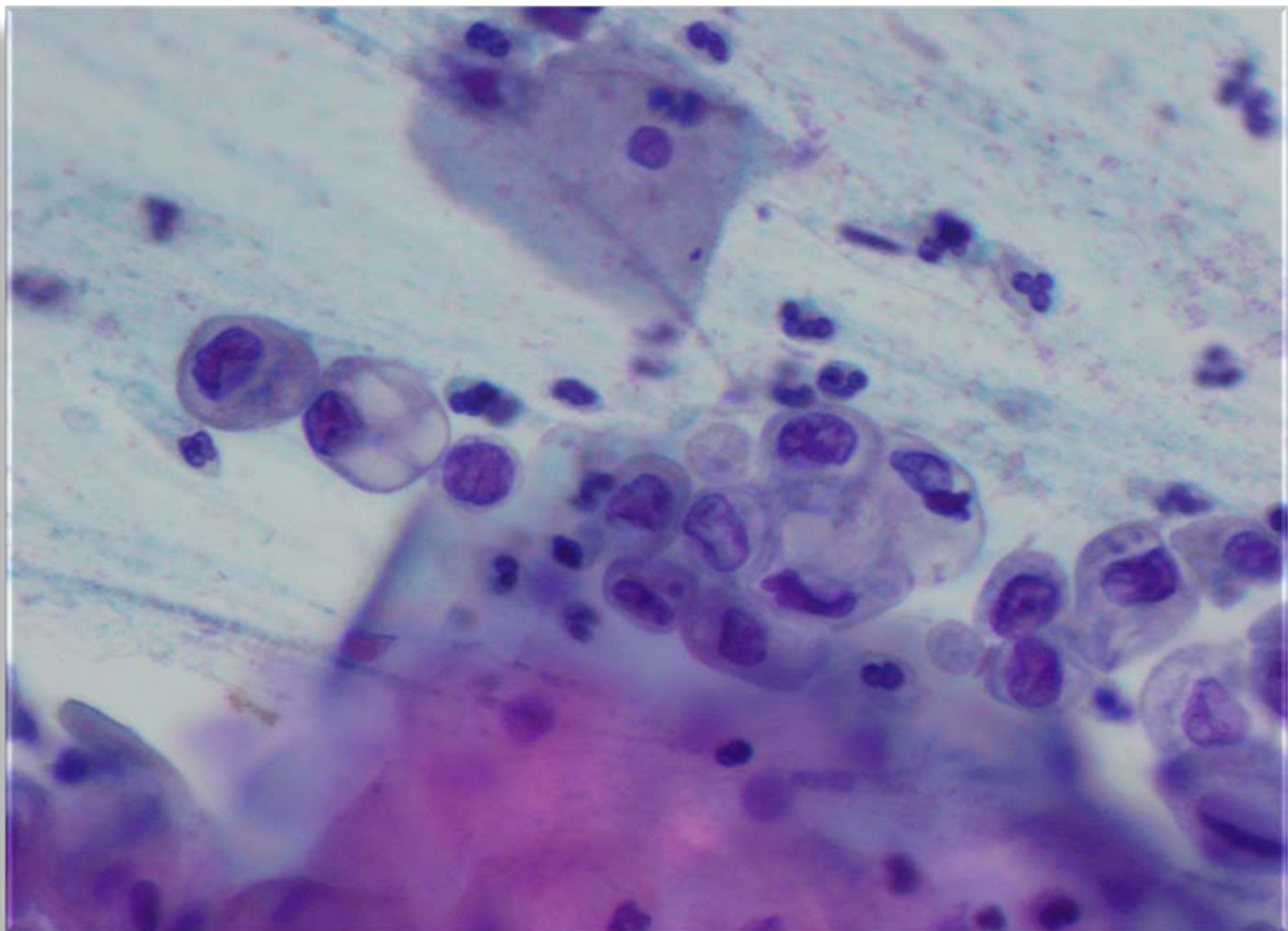
**DUM: 30/04/09**

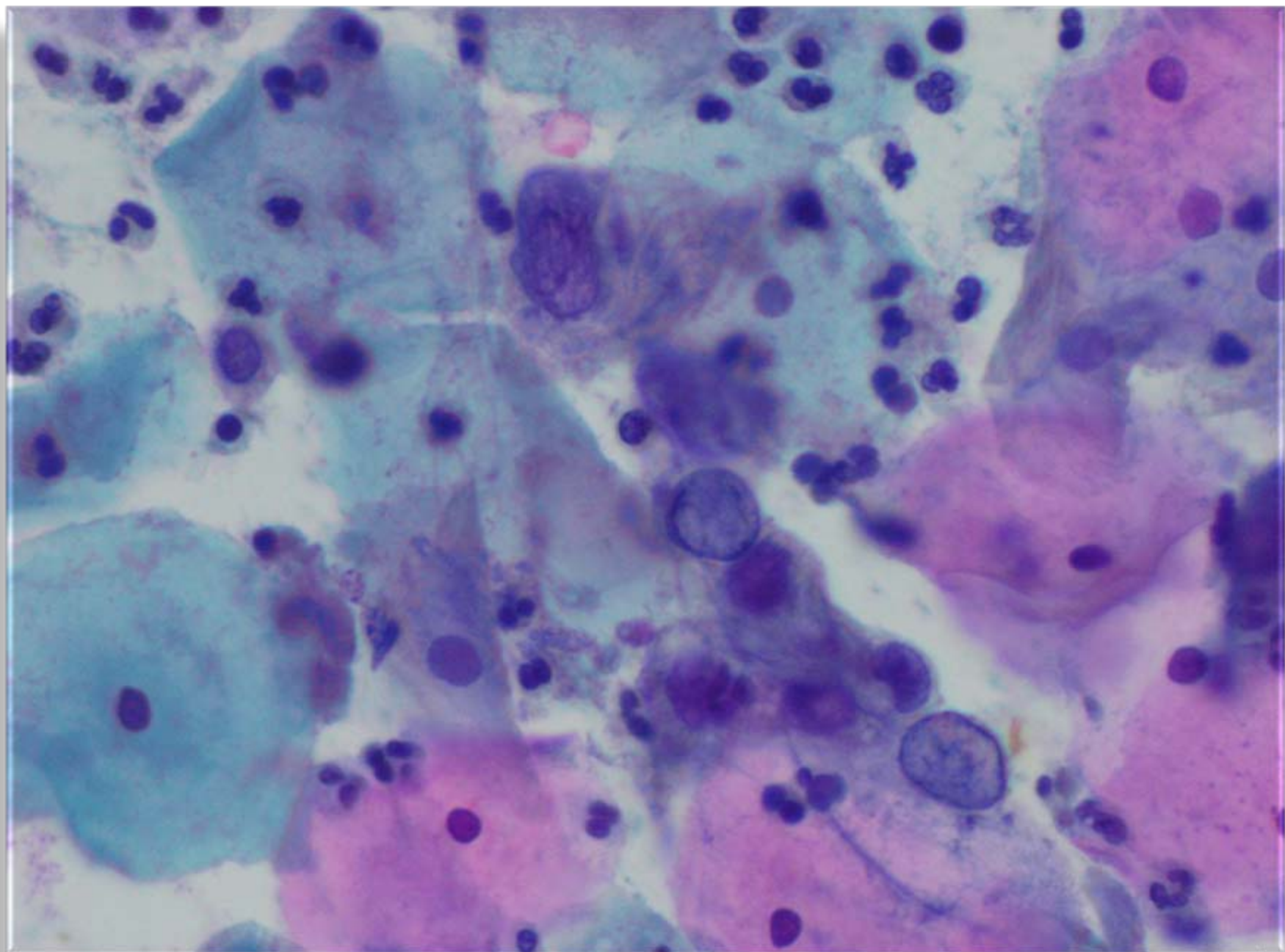
**Coleta: 20/05/09**

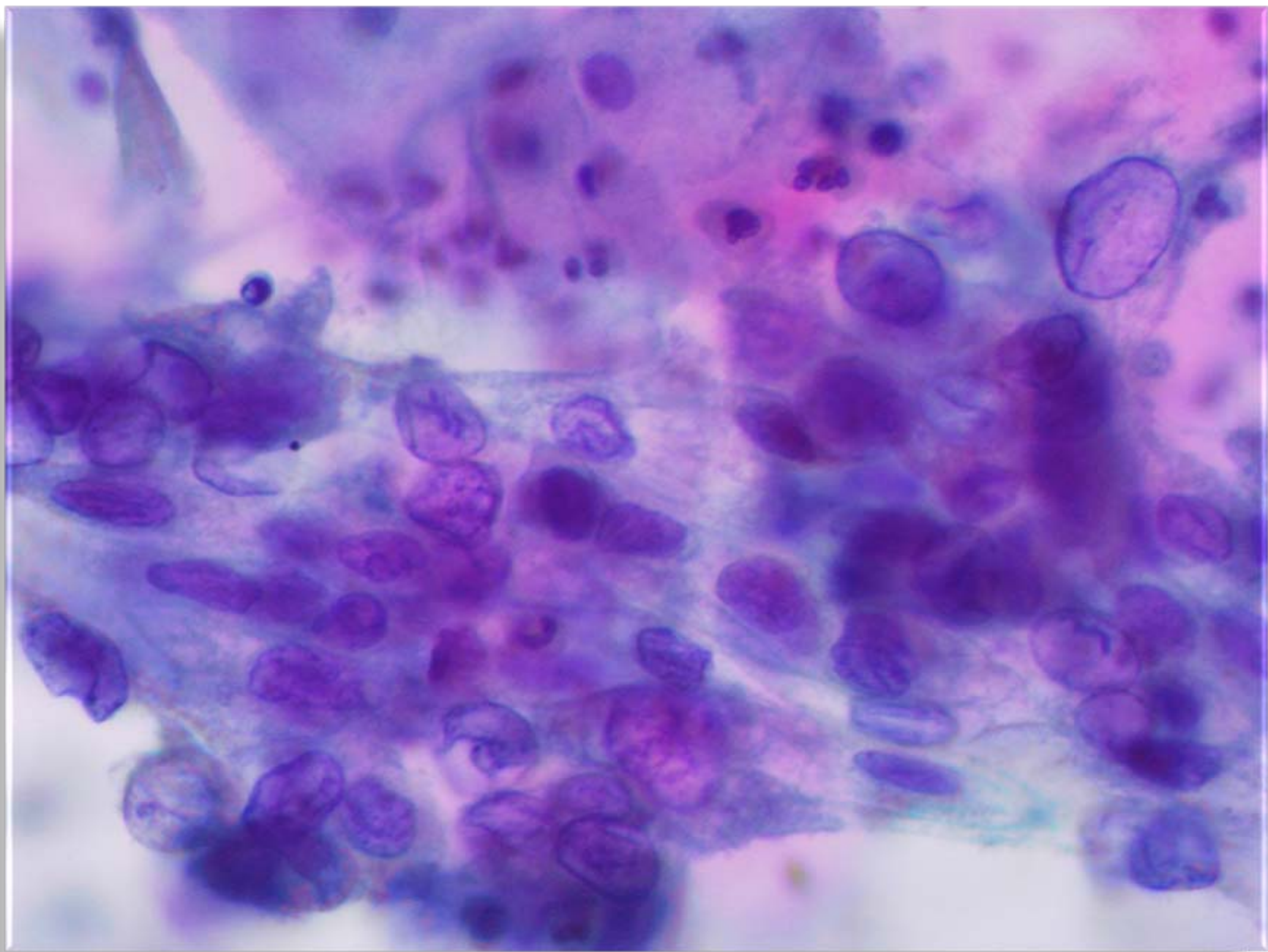




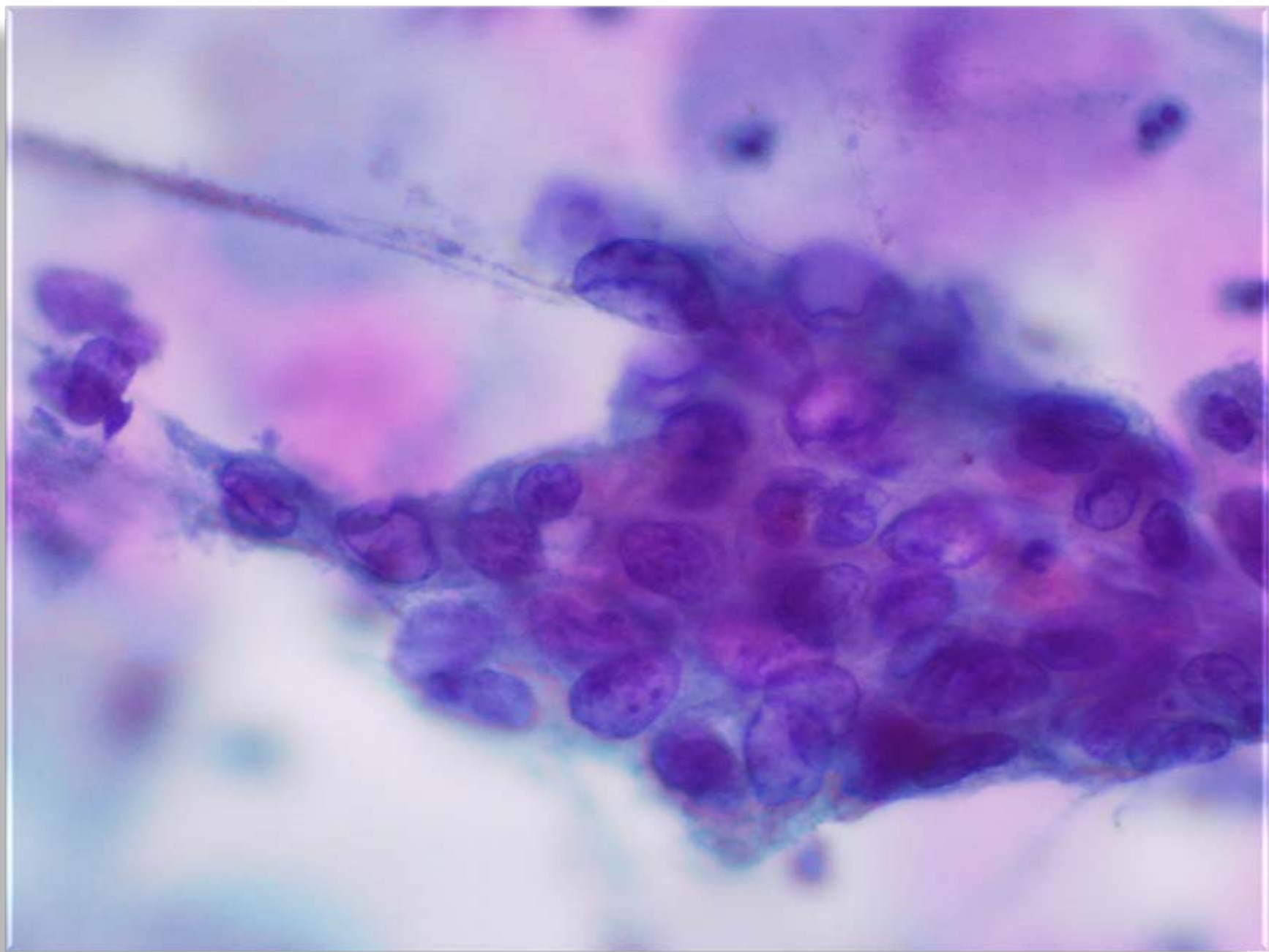













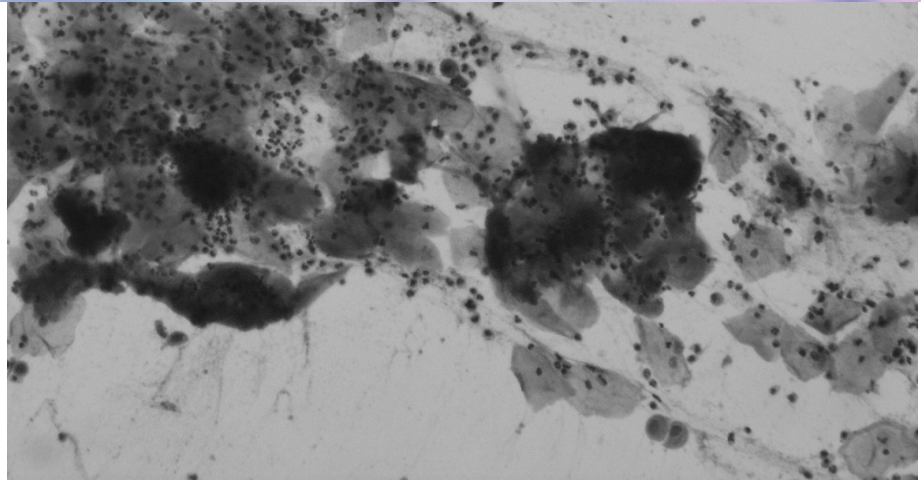
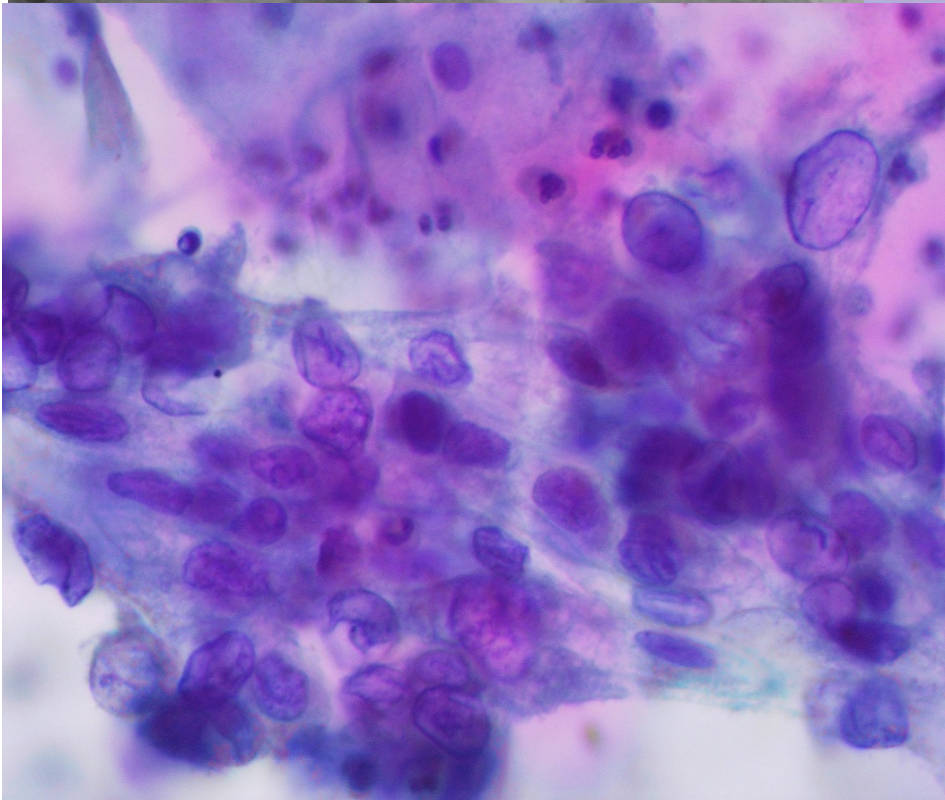
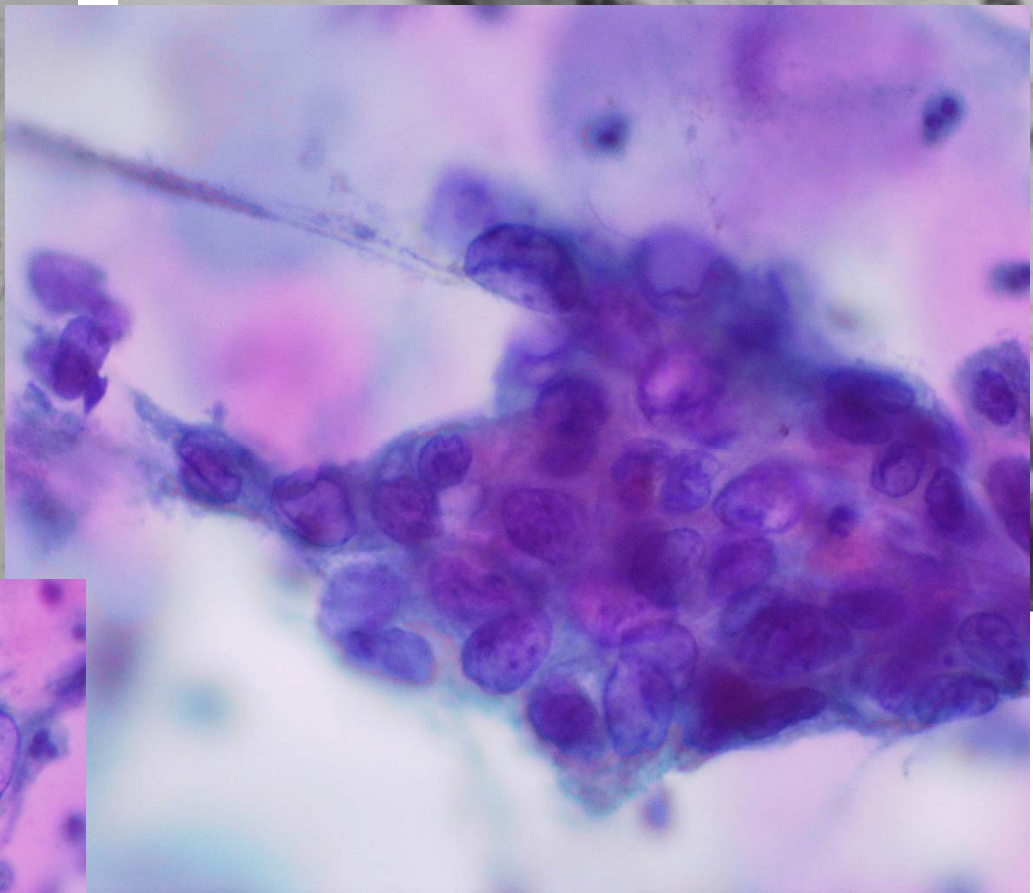
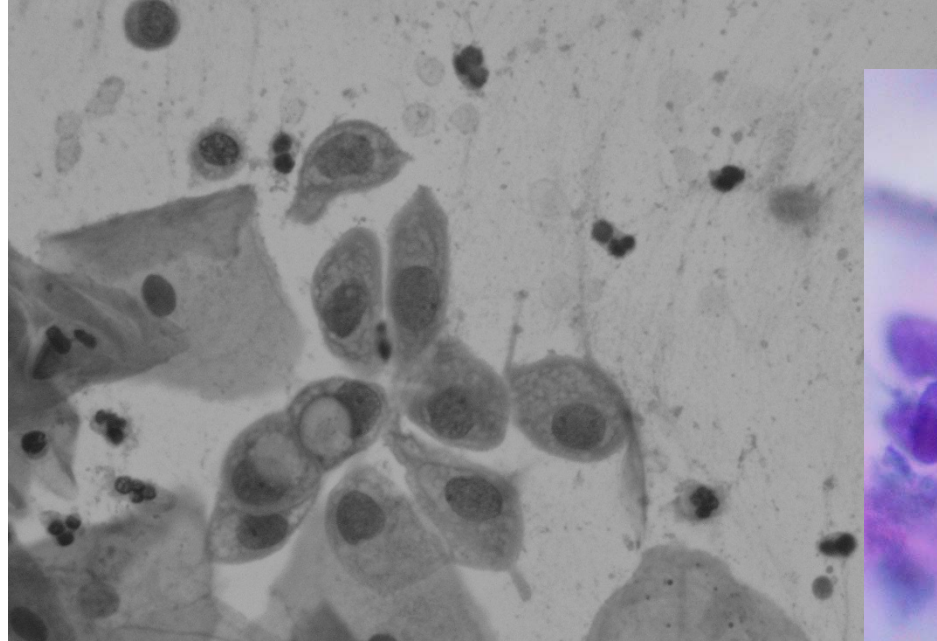
# Diagnóstico Citopatológico



## **Citologia Inflamatória**

**Reparação (associada ao uso de DIU)**

***Actinomyces sp e Chlamydia sp***

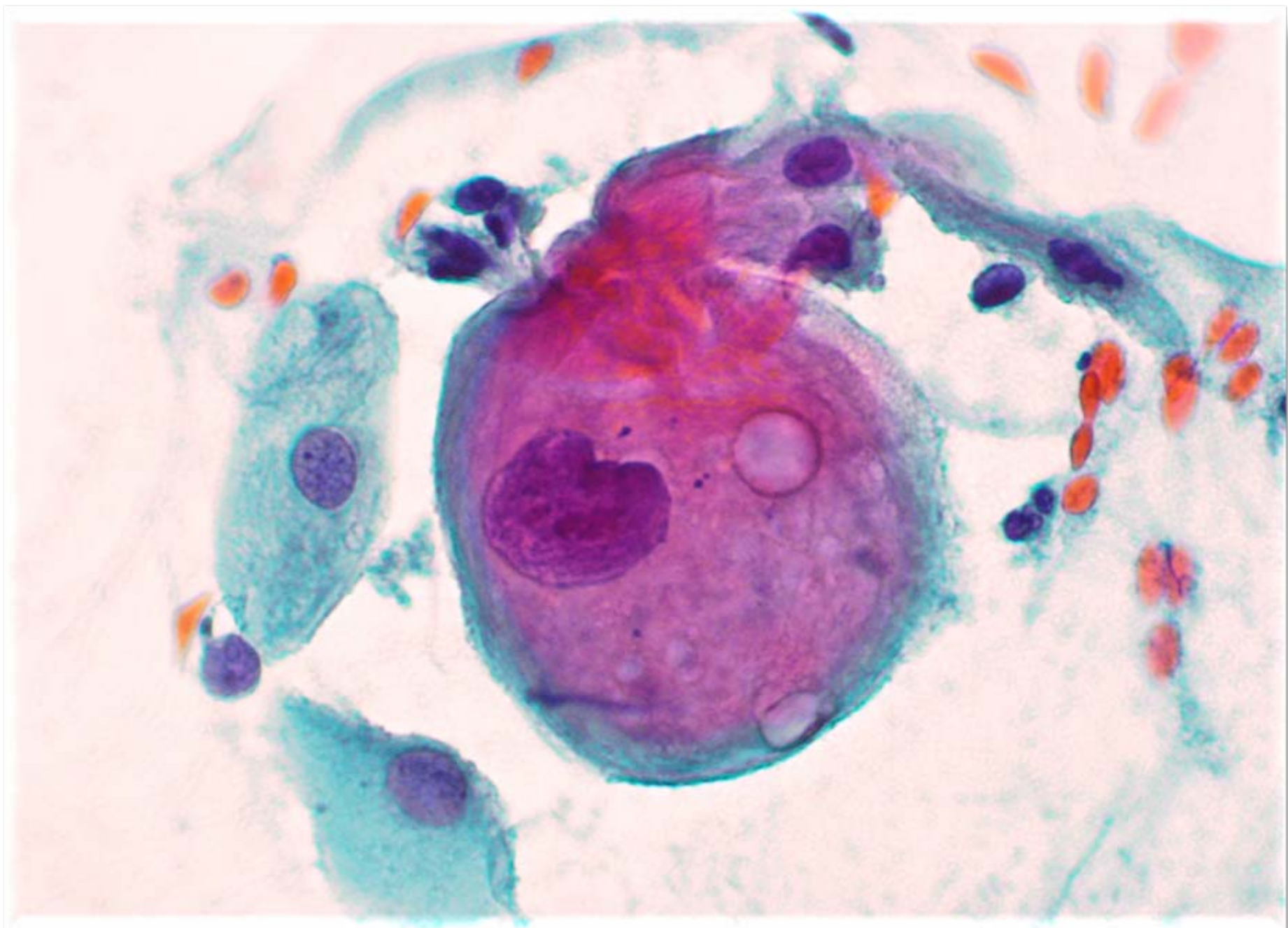


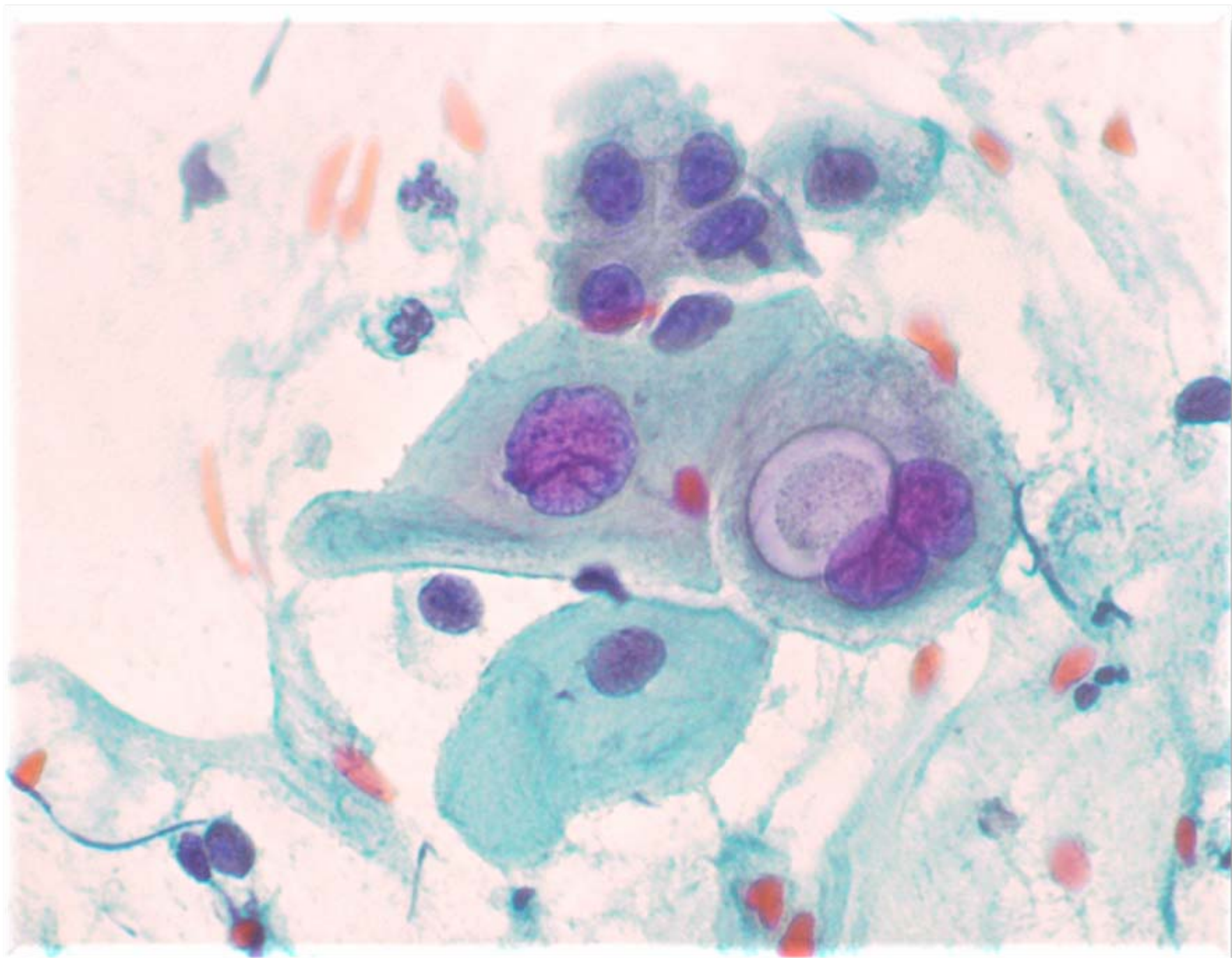
## **CASO 2**

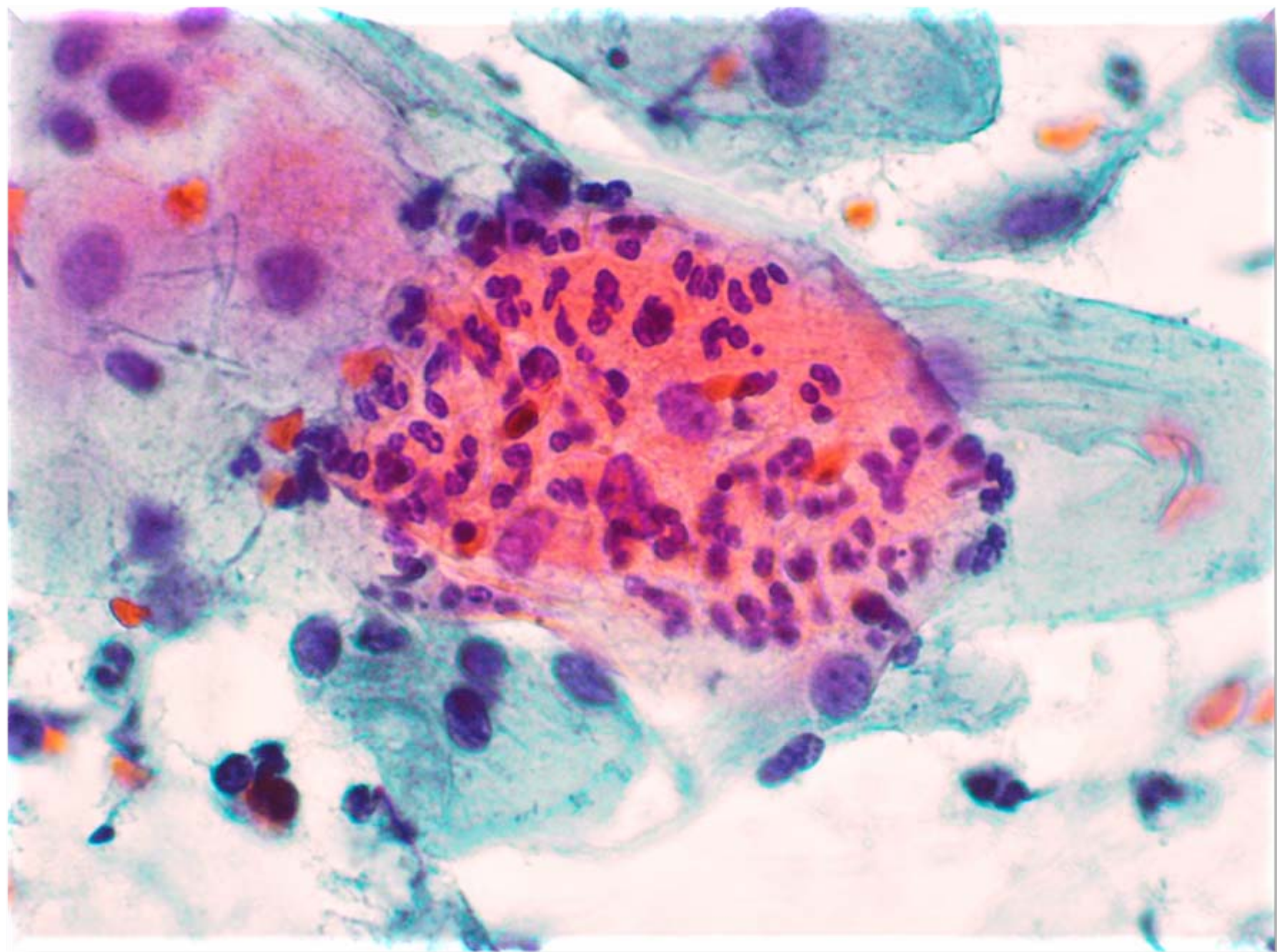
**Paciente de 57 años**

**Histerectomía: 8 meses**

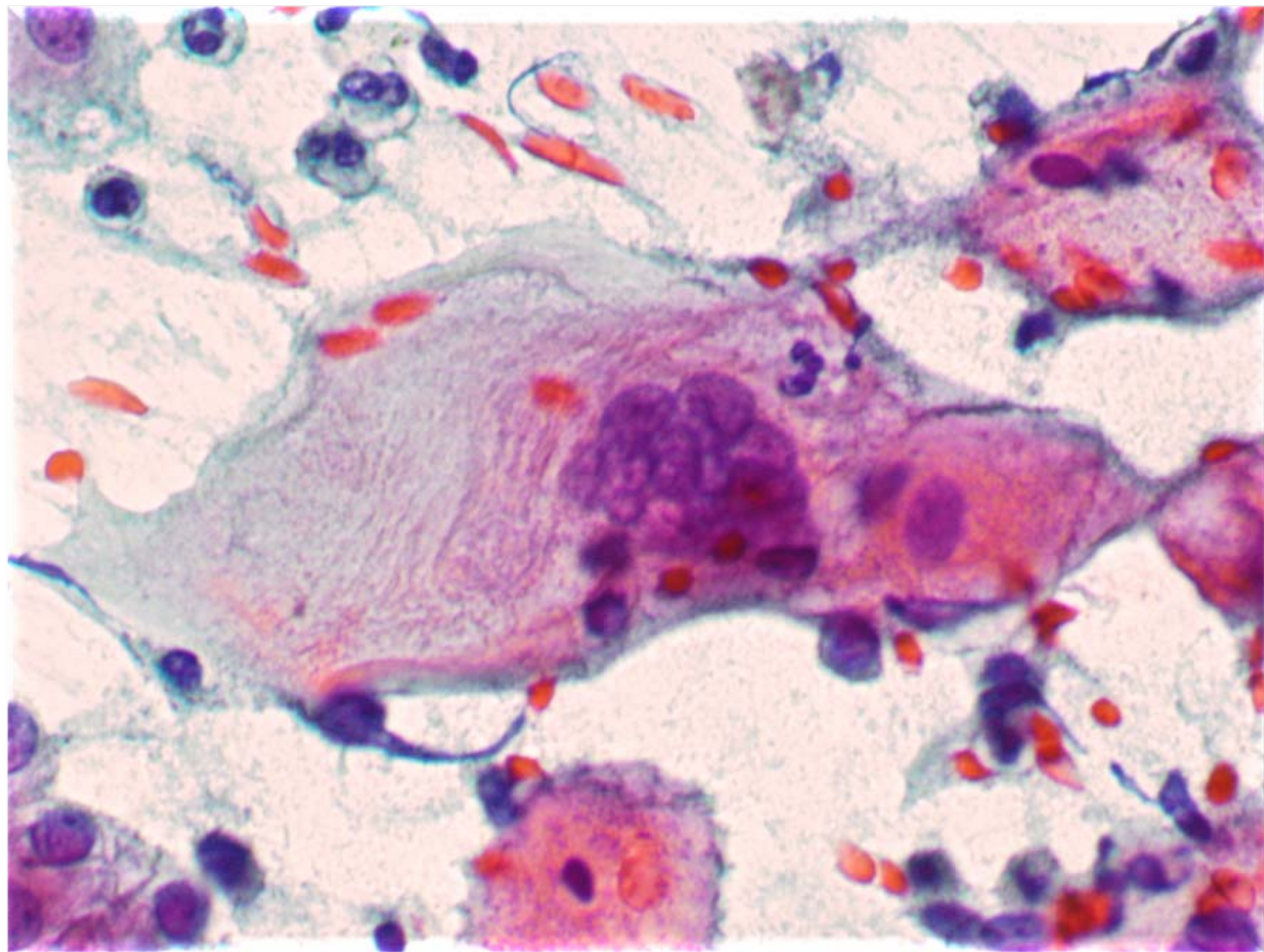


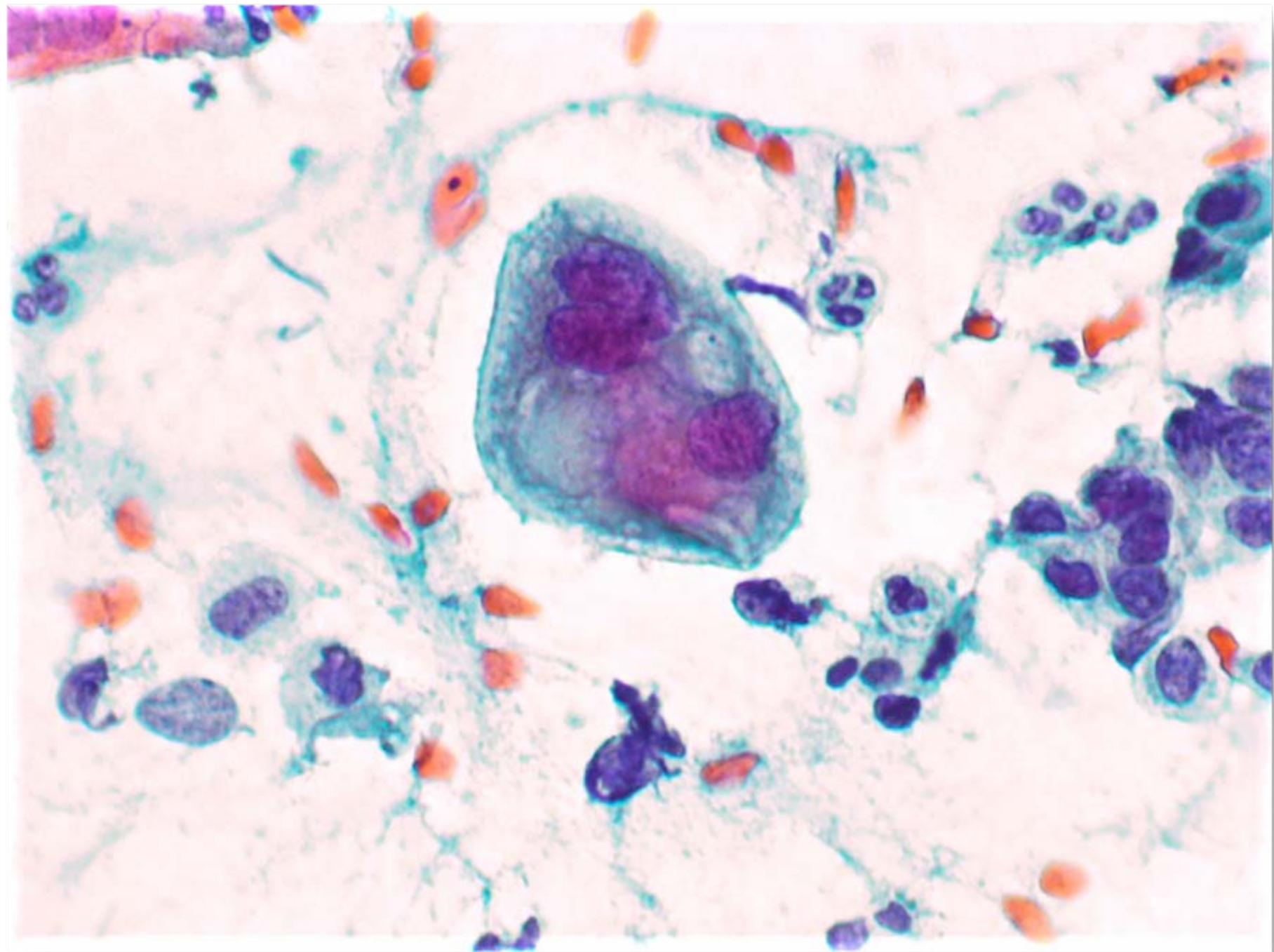


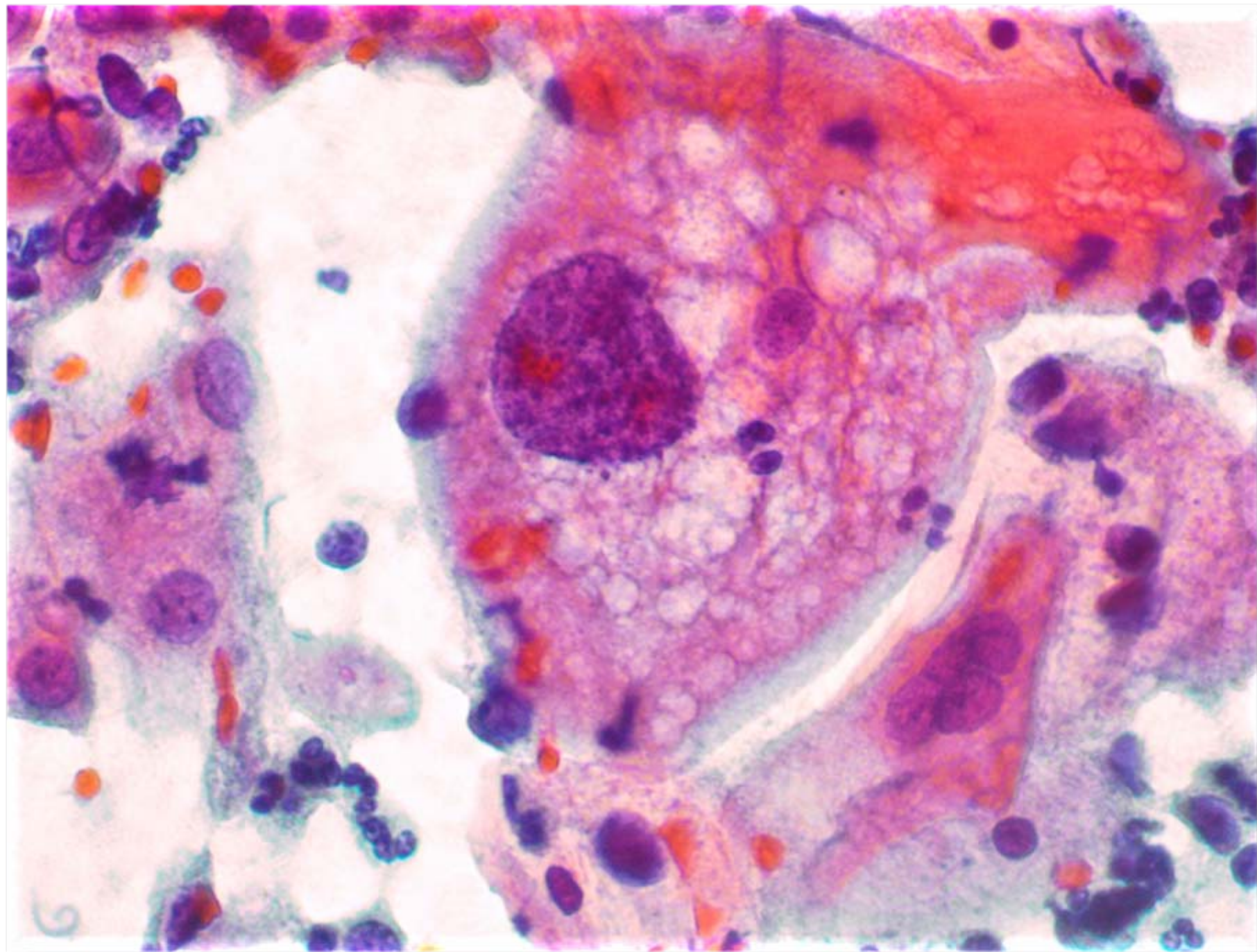


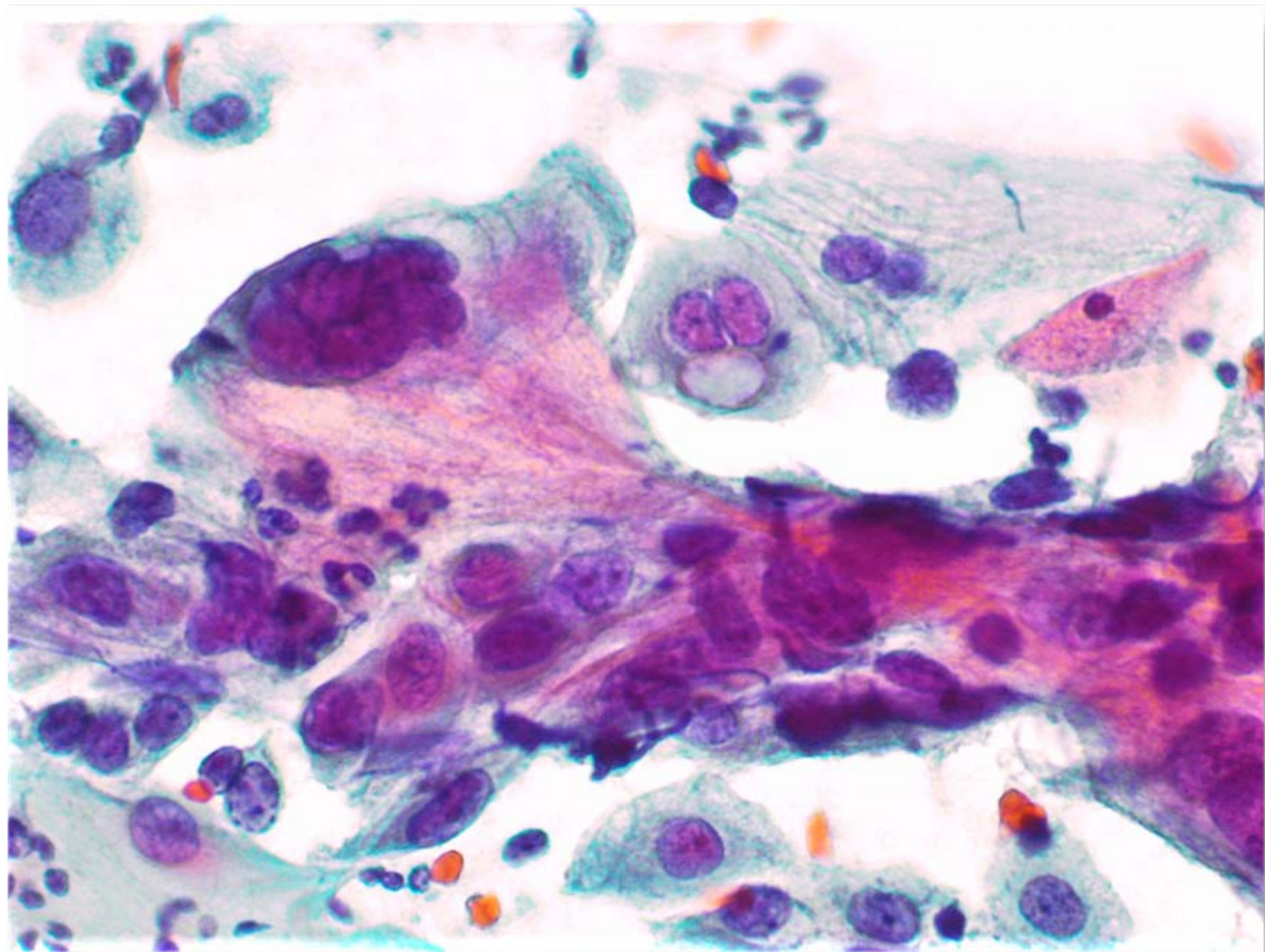









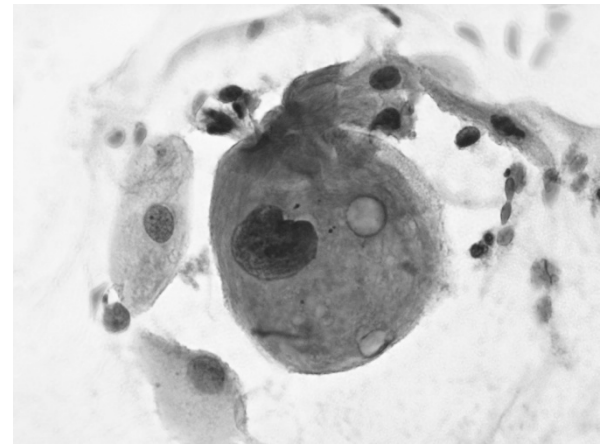
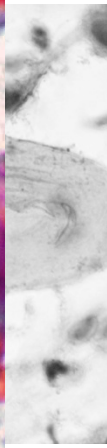
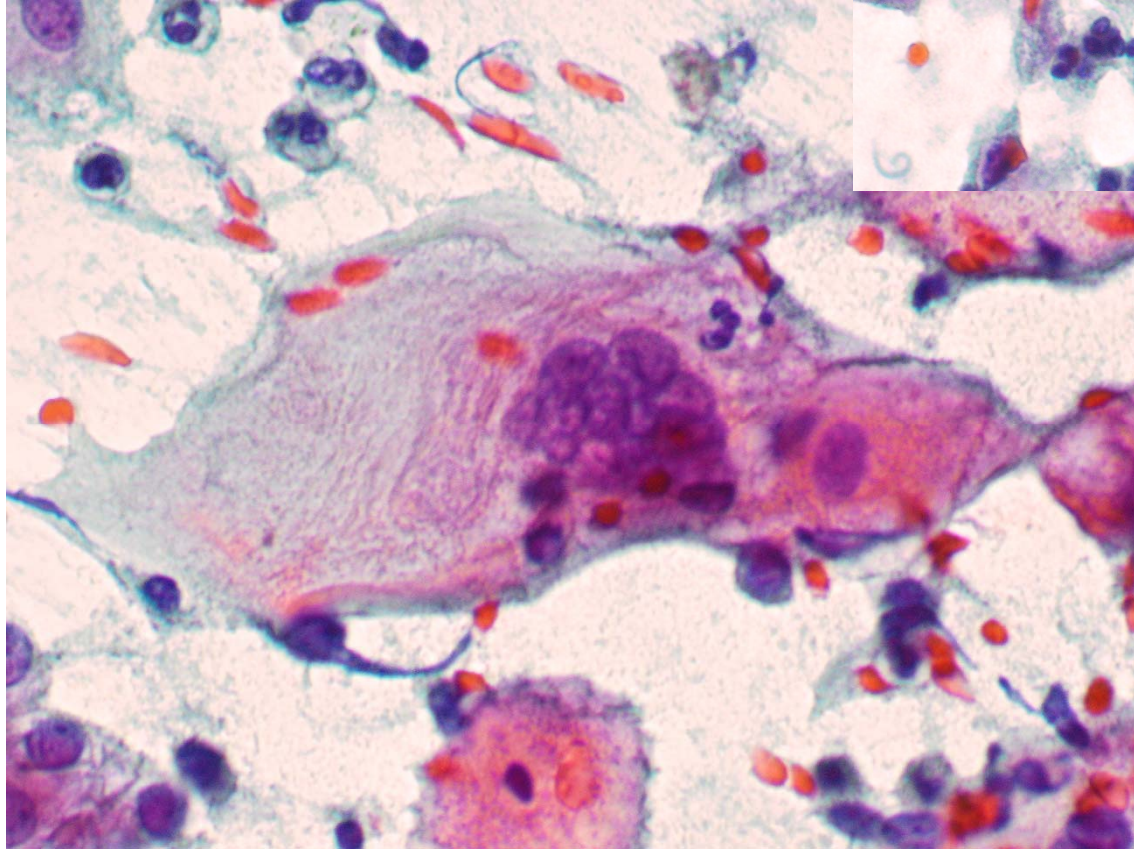
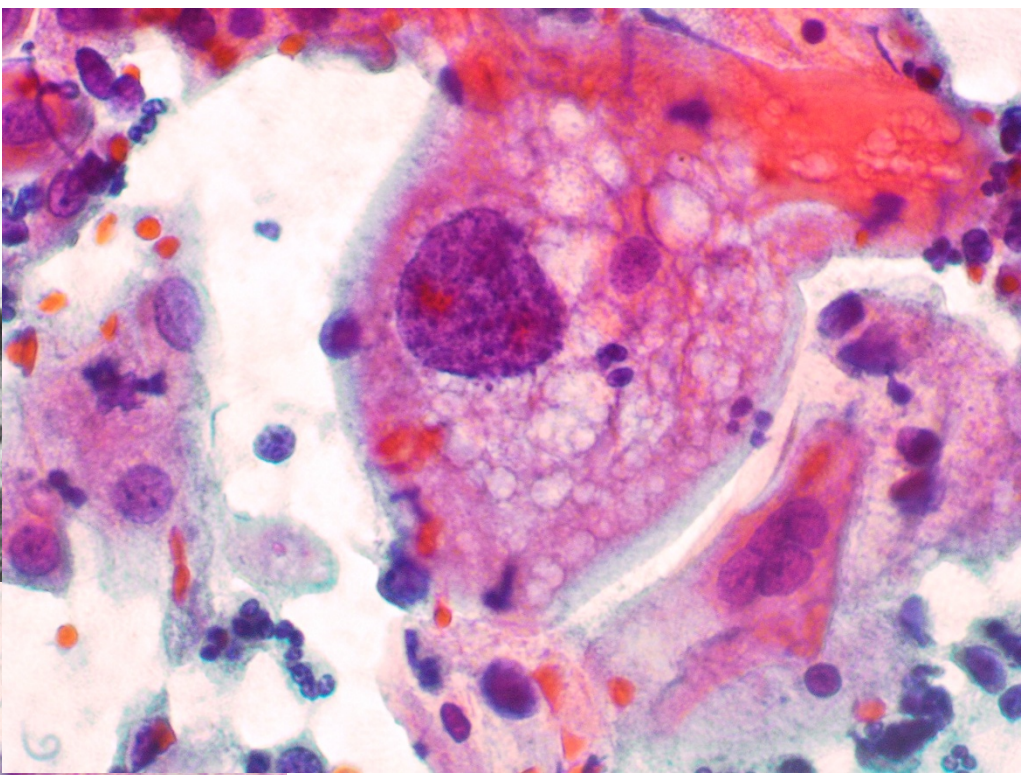
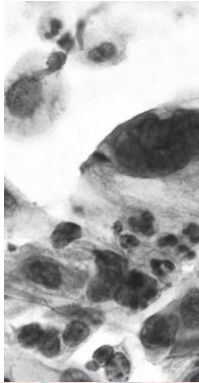
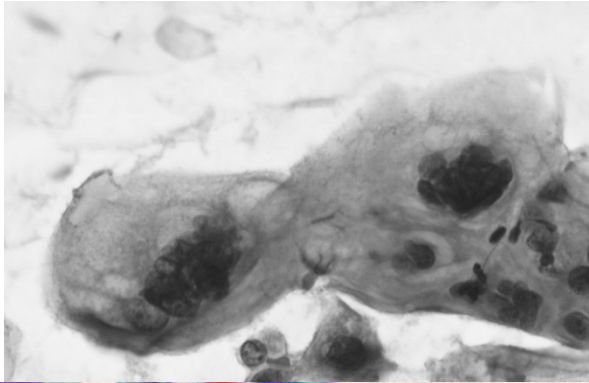




# Diagnóstico Citopatológico

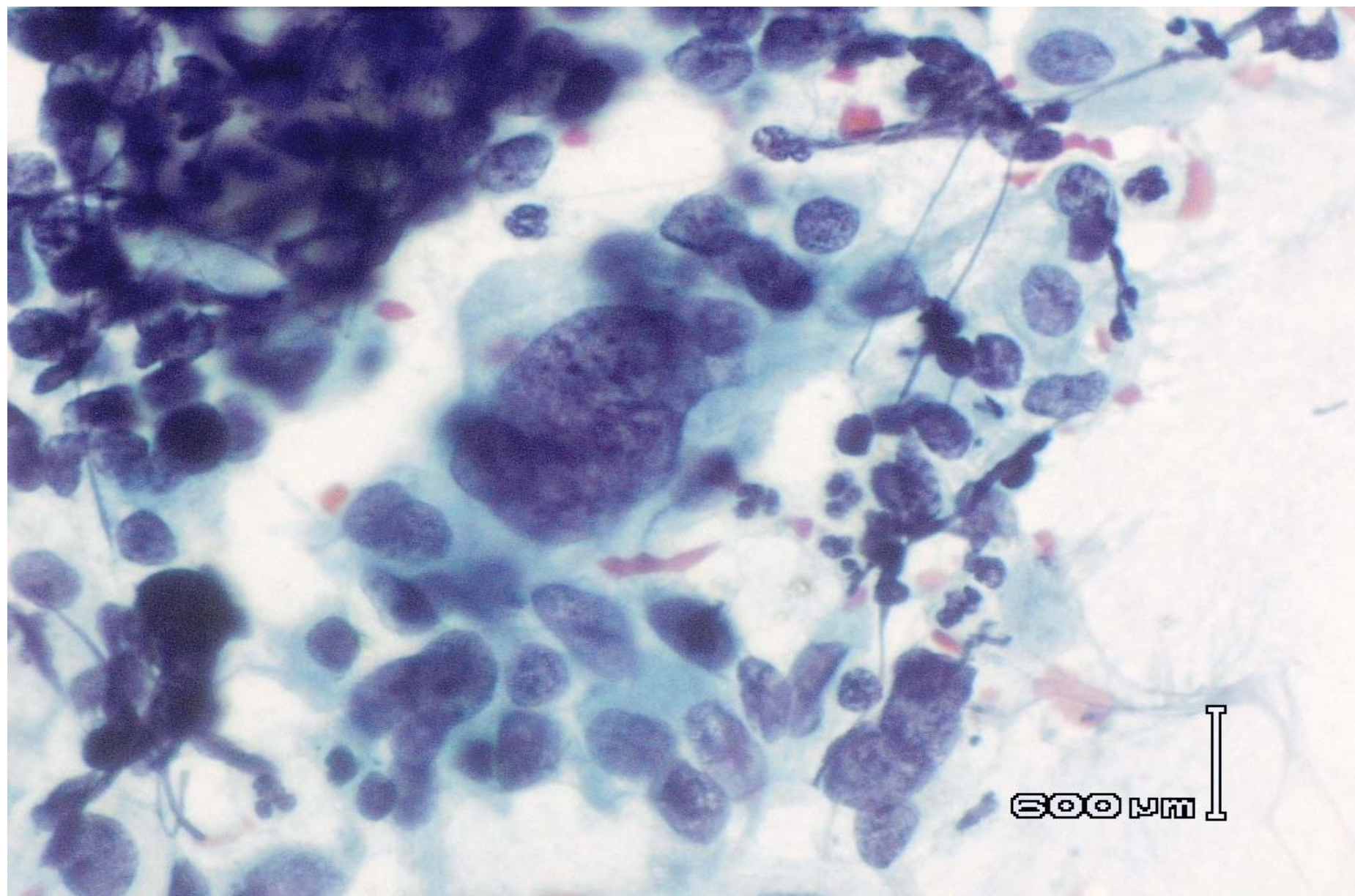


**Alterações celulares pós-radioterapia**

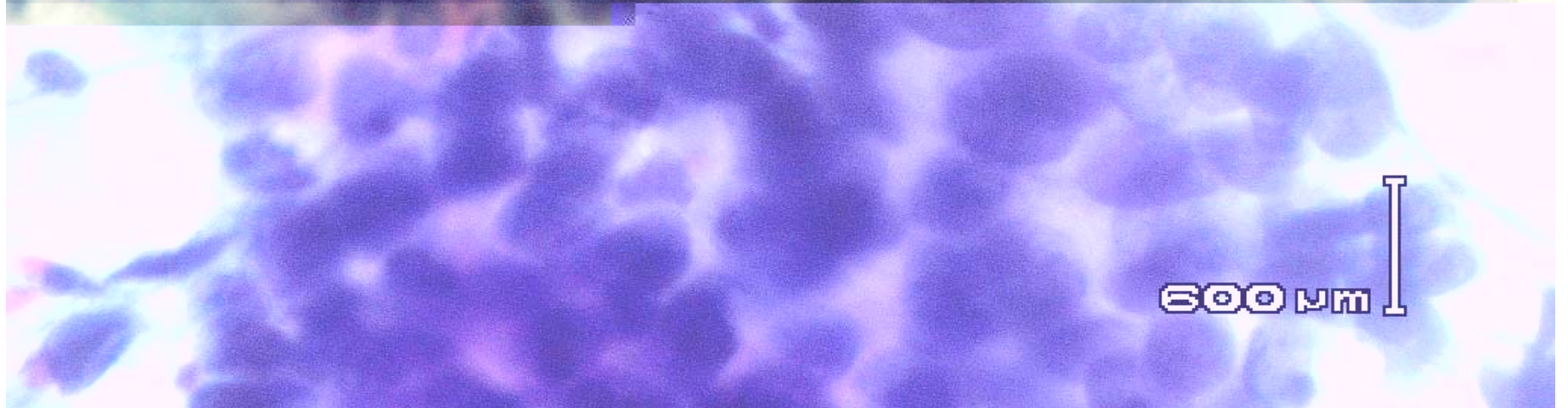
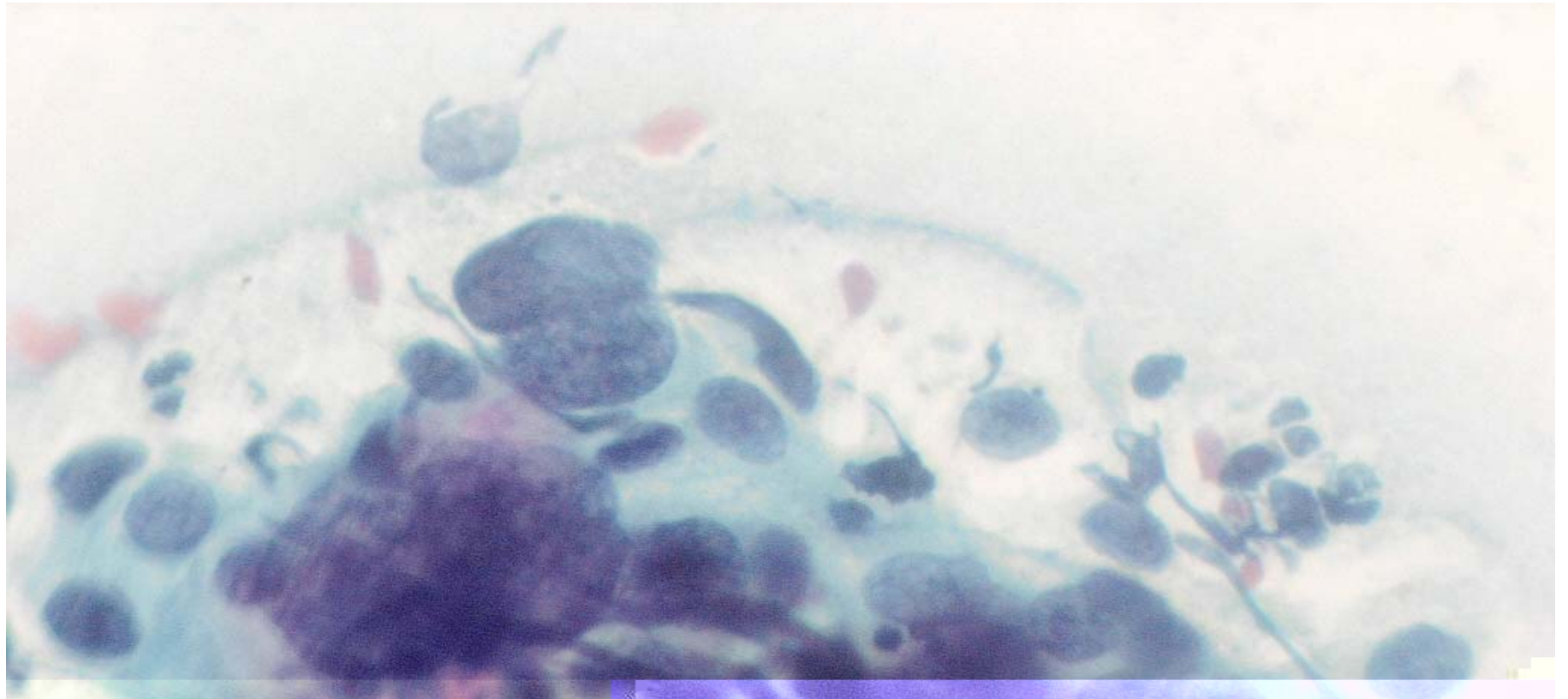


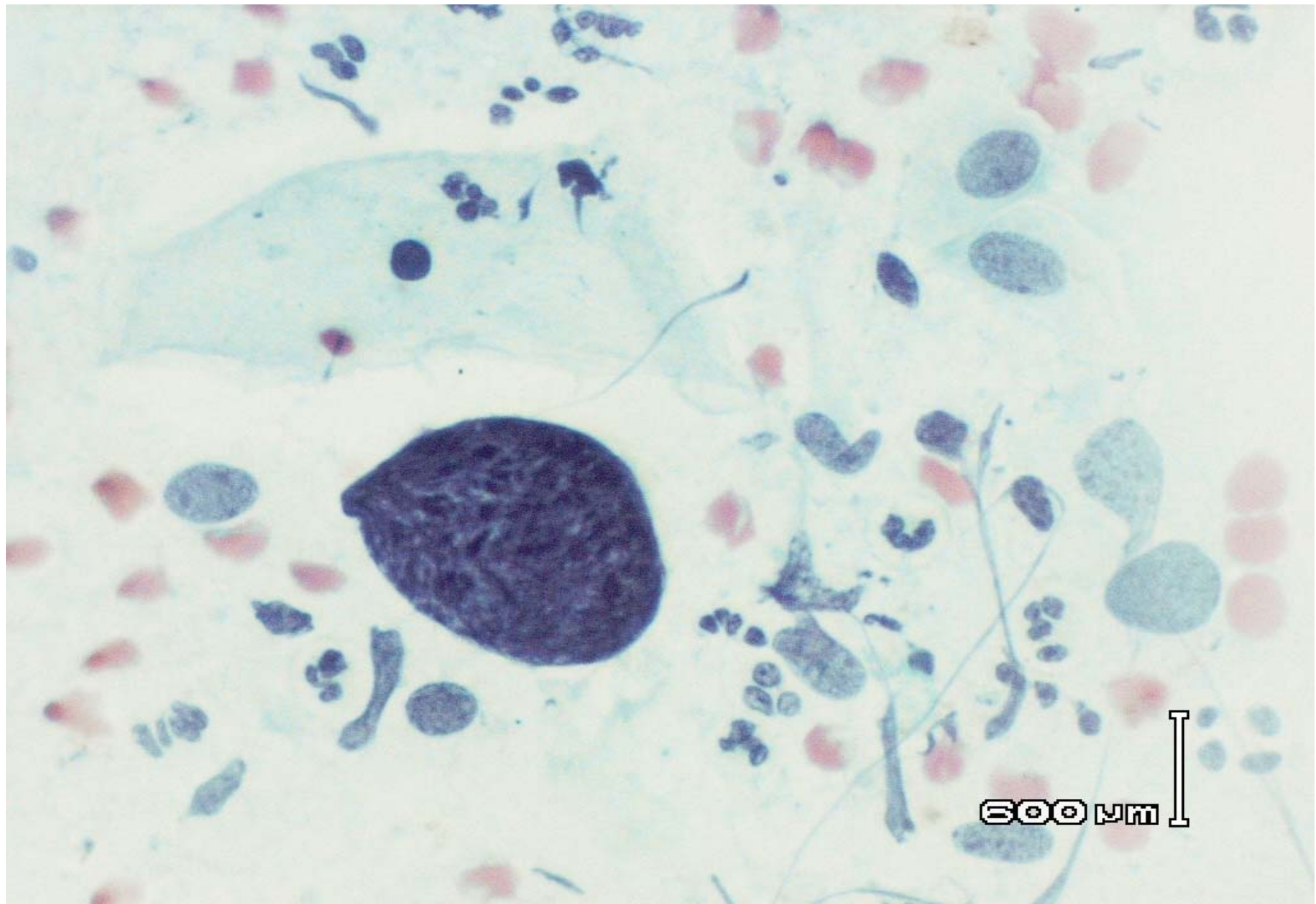
## **CASO 3**

**Idade: 76 anos**  
**Radioterapia**

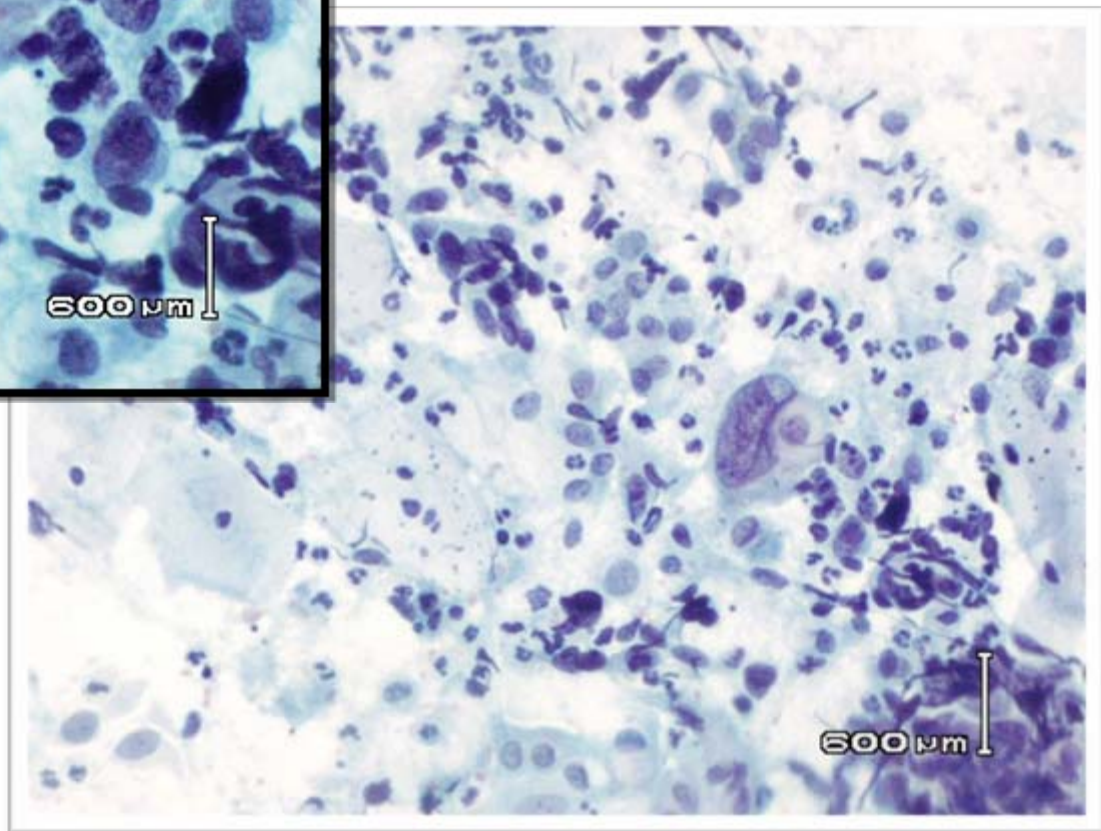
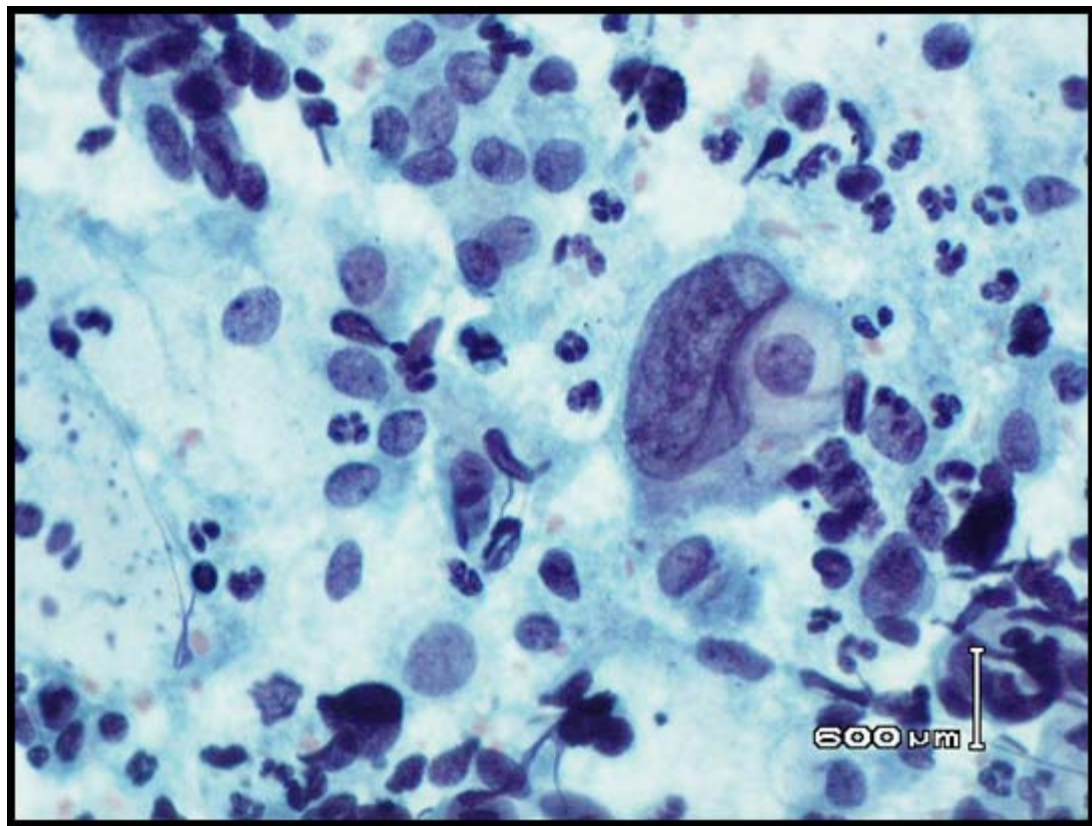


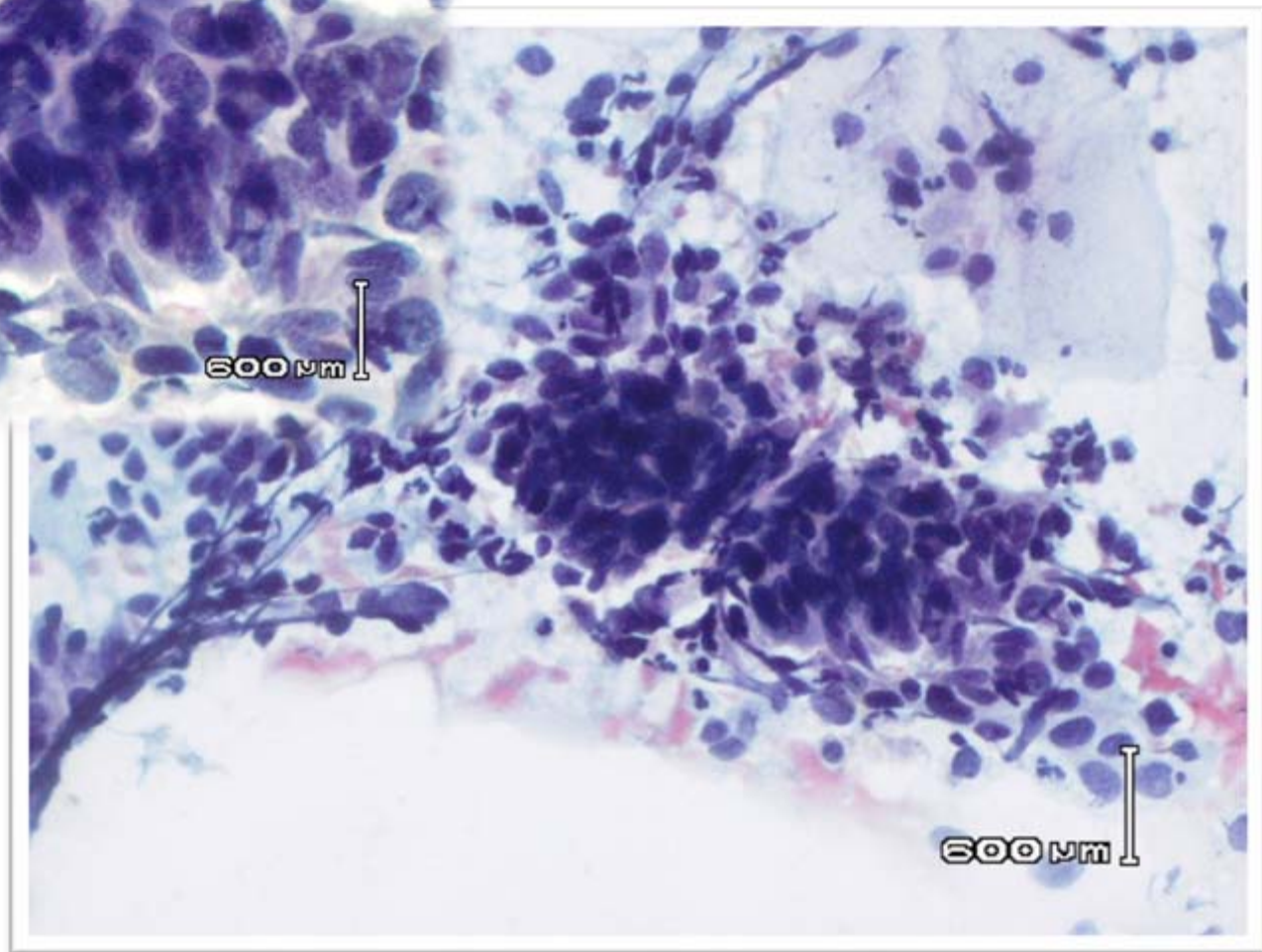
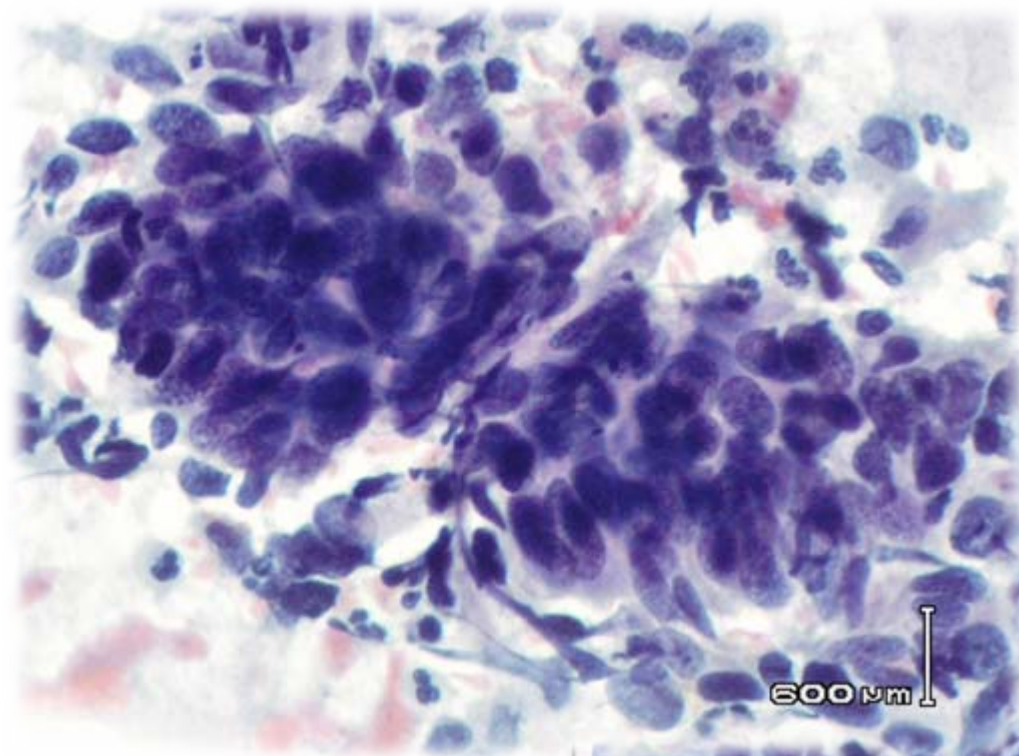


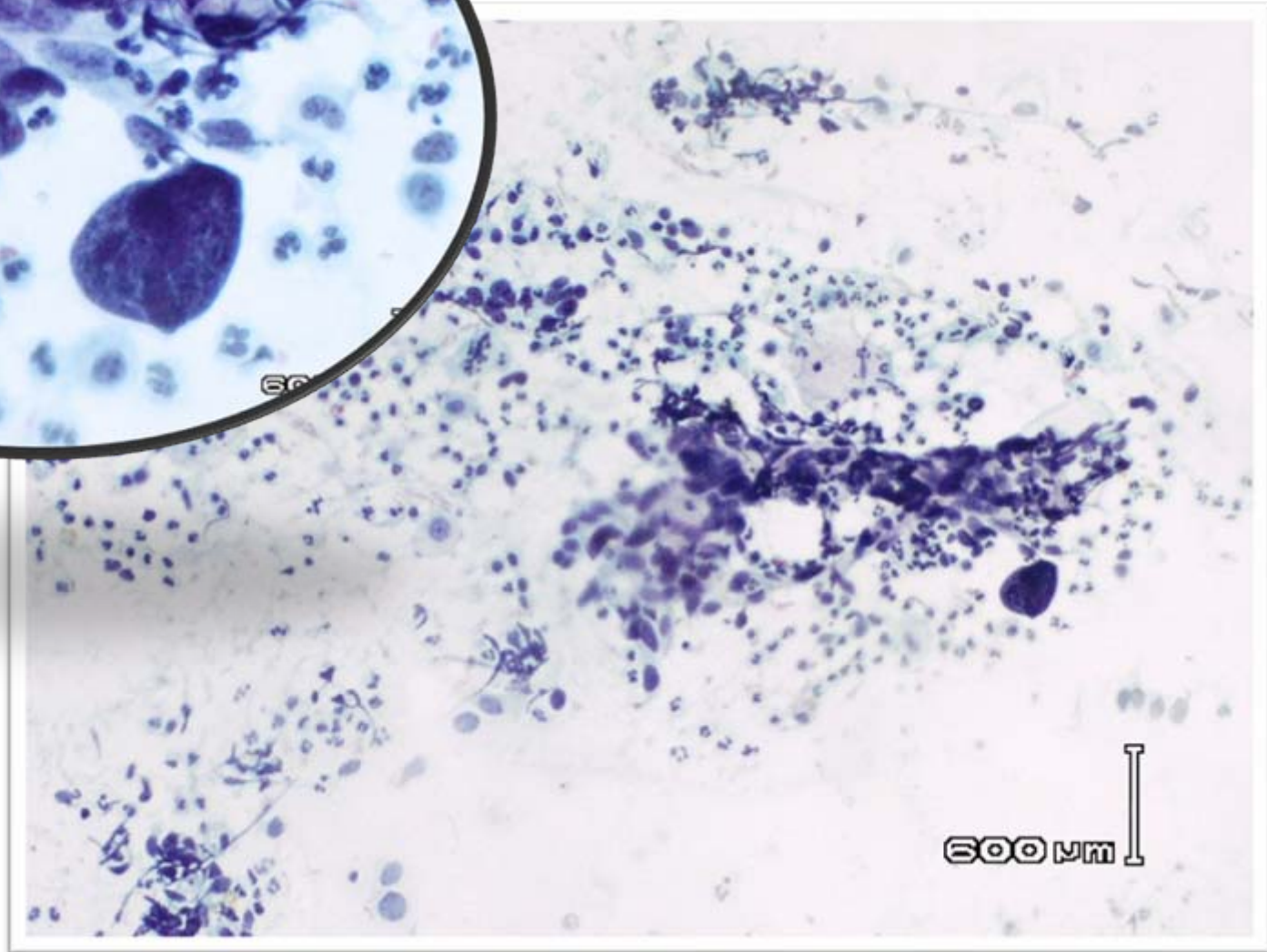
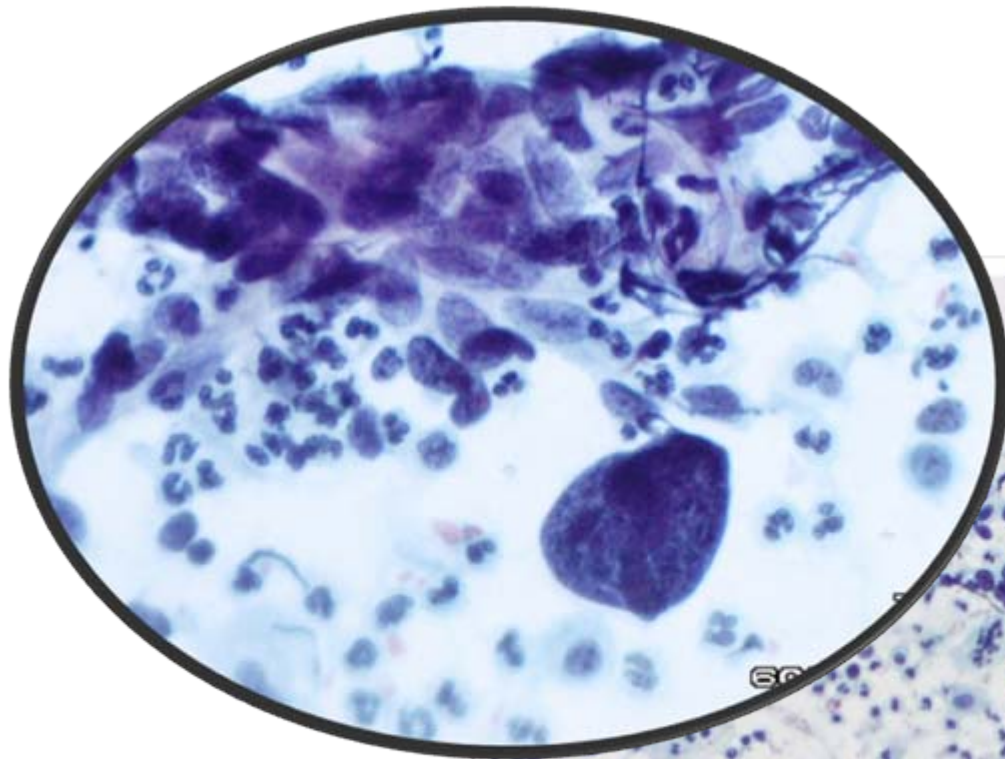


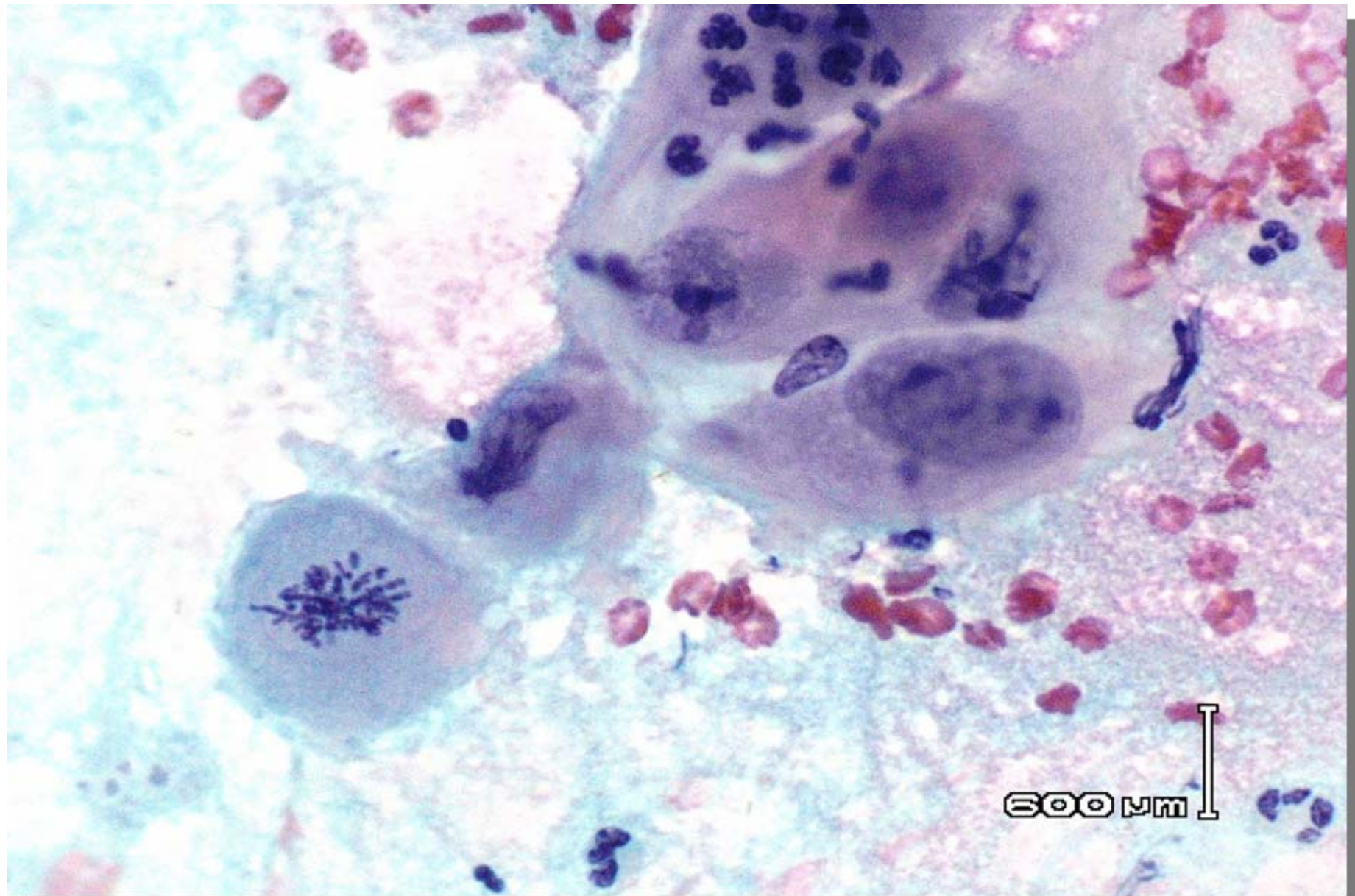


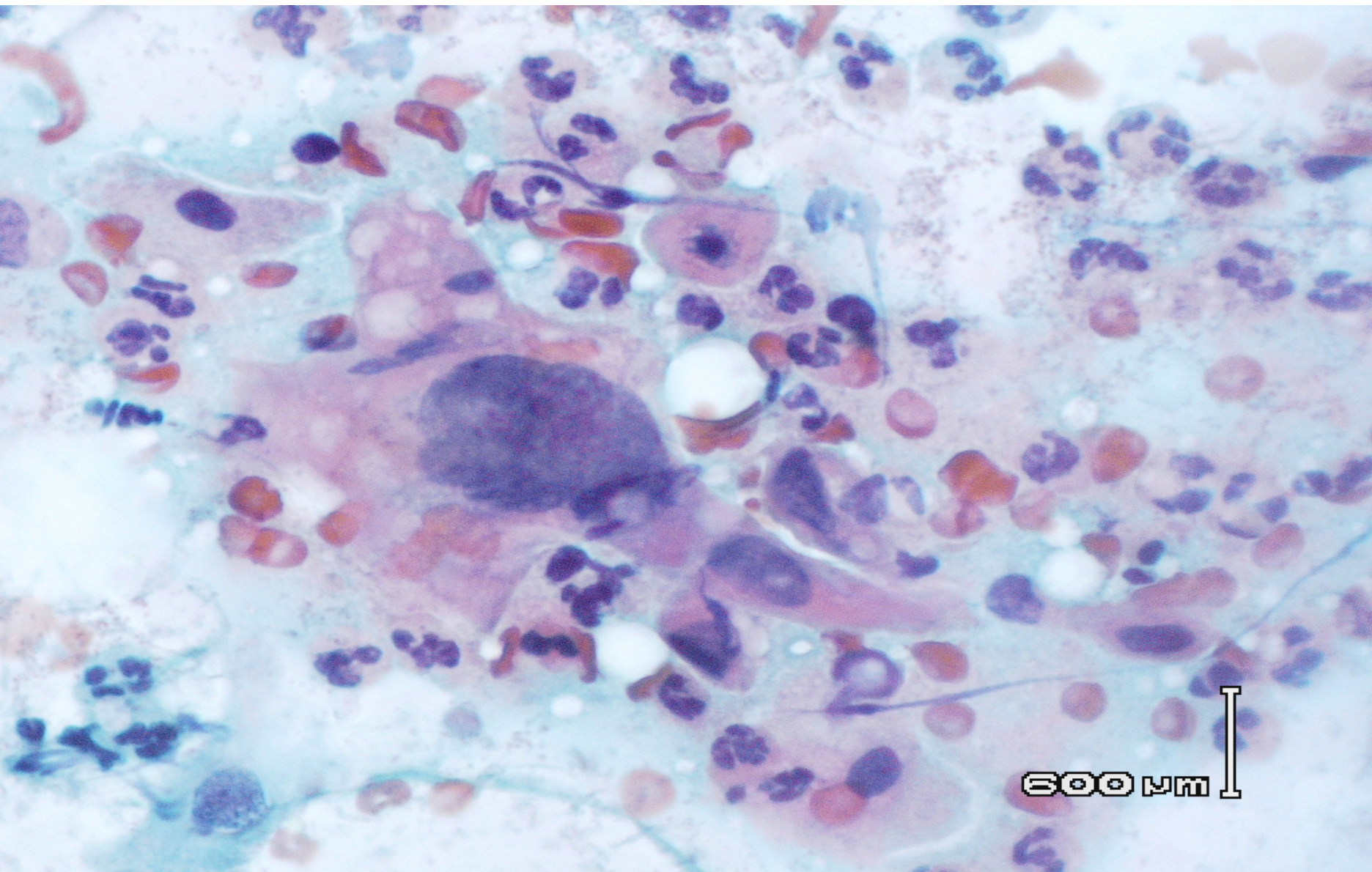
600 μm



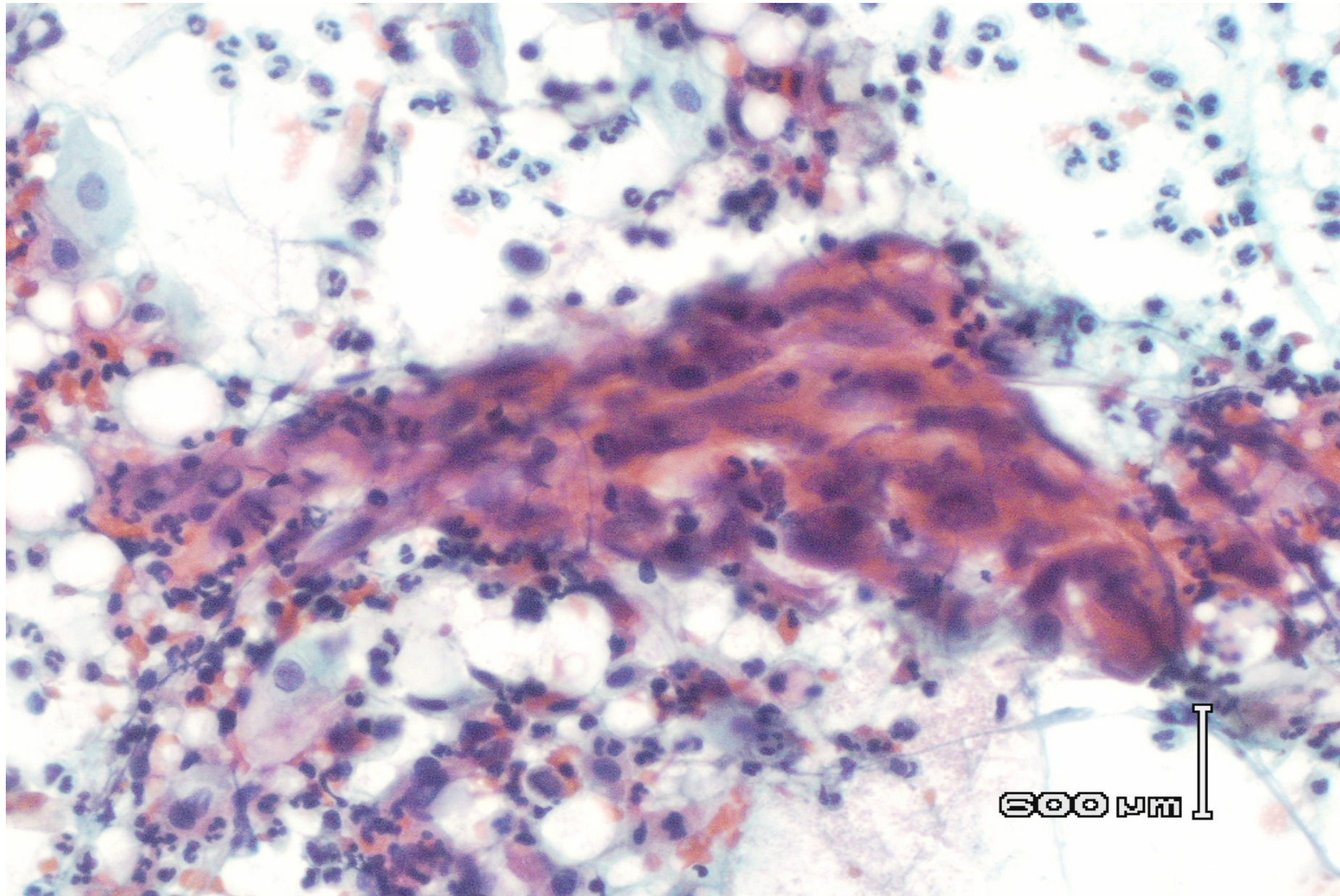









600 nm

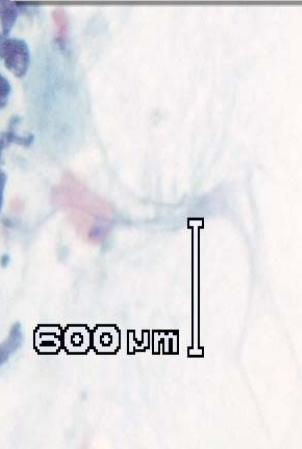
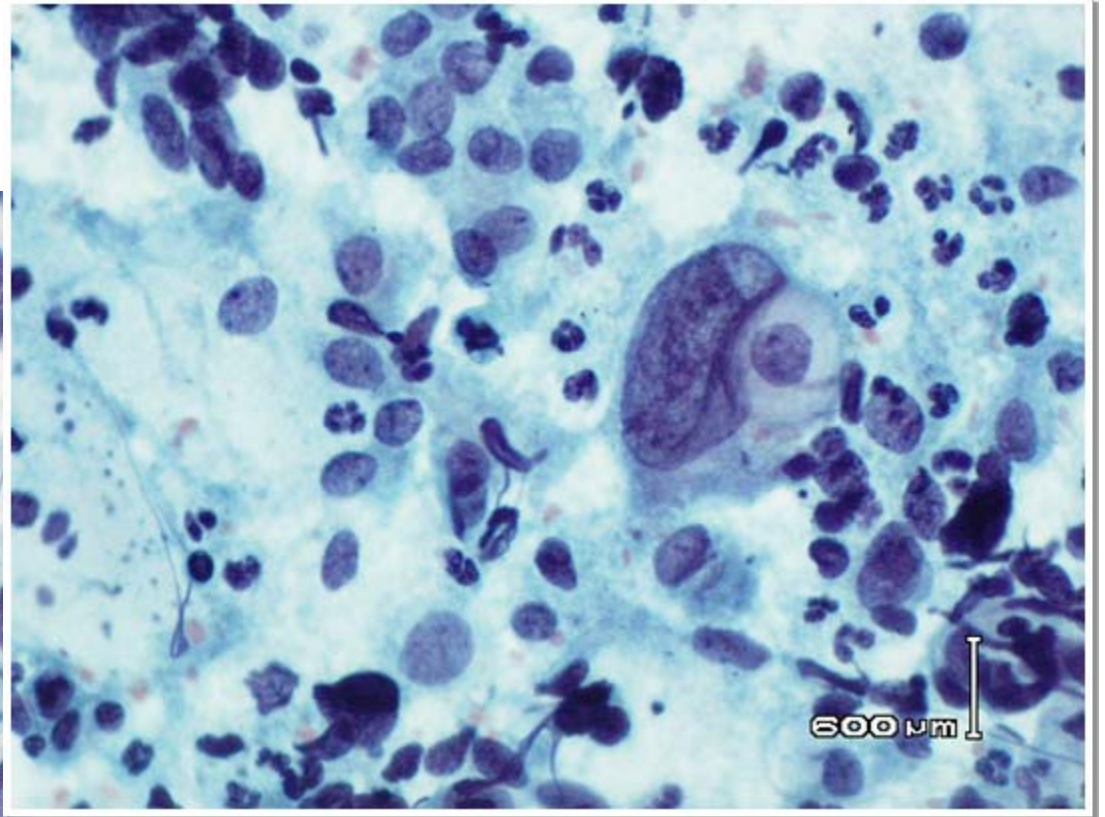
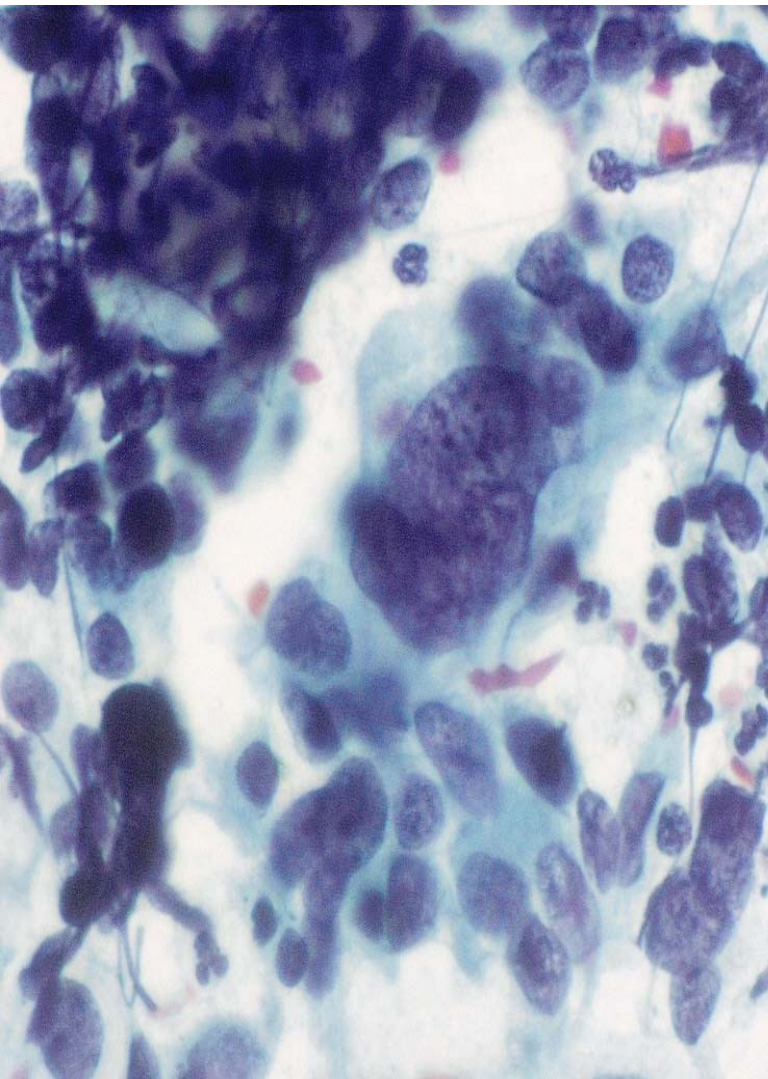




# Diagnóstico Citopatológico



**Carcinoma Invasor**

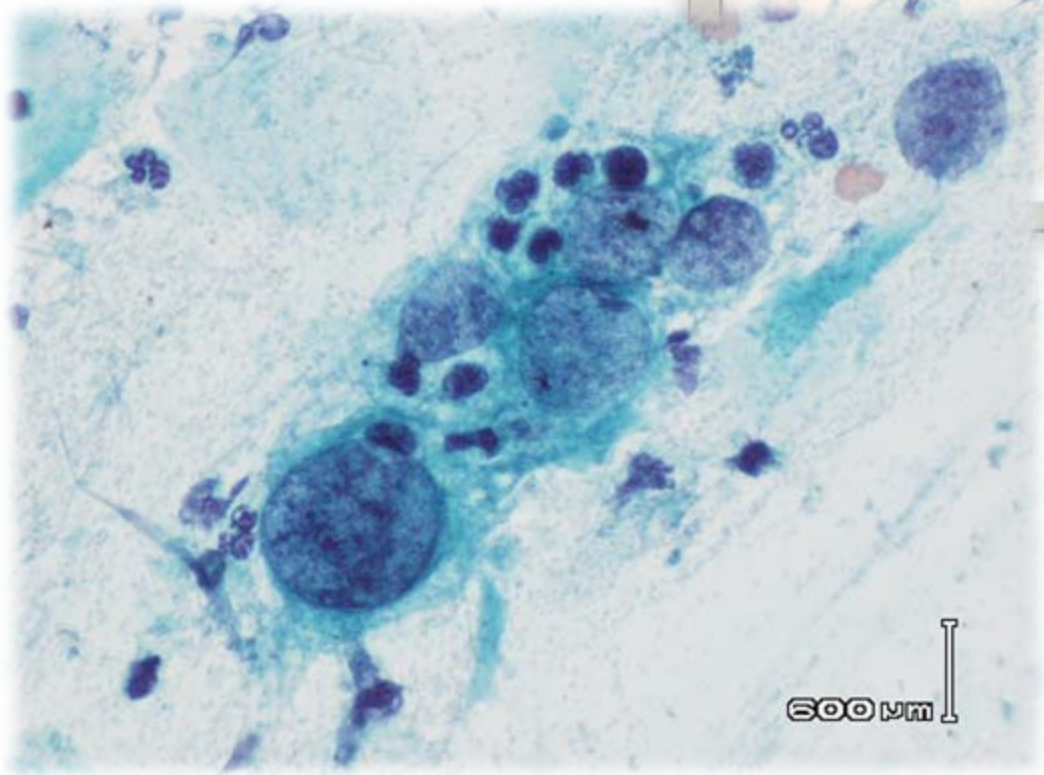
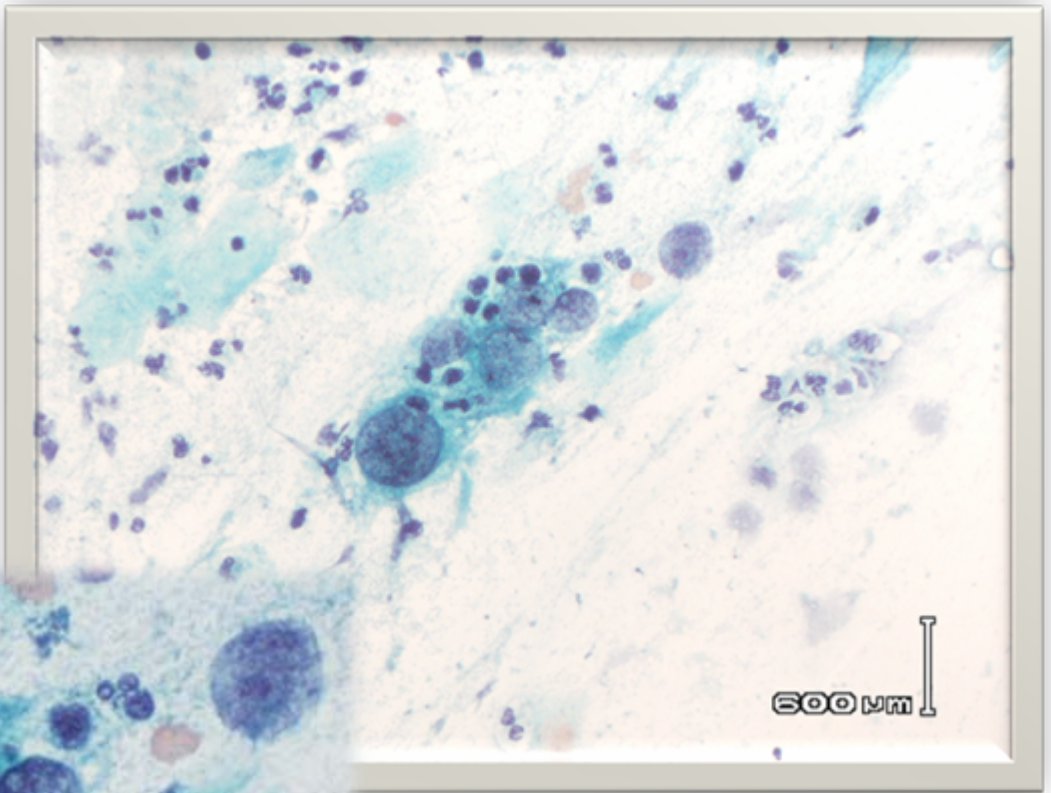


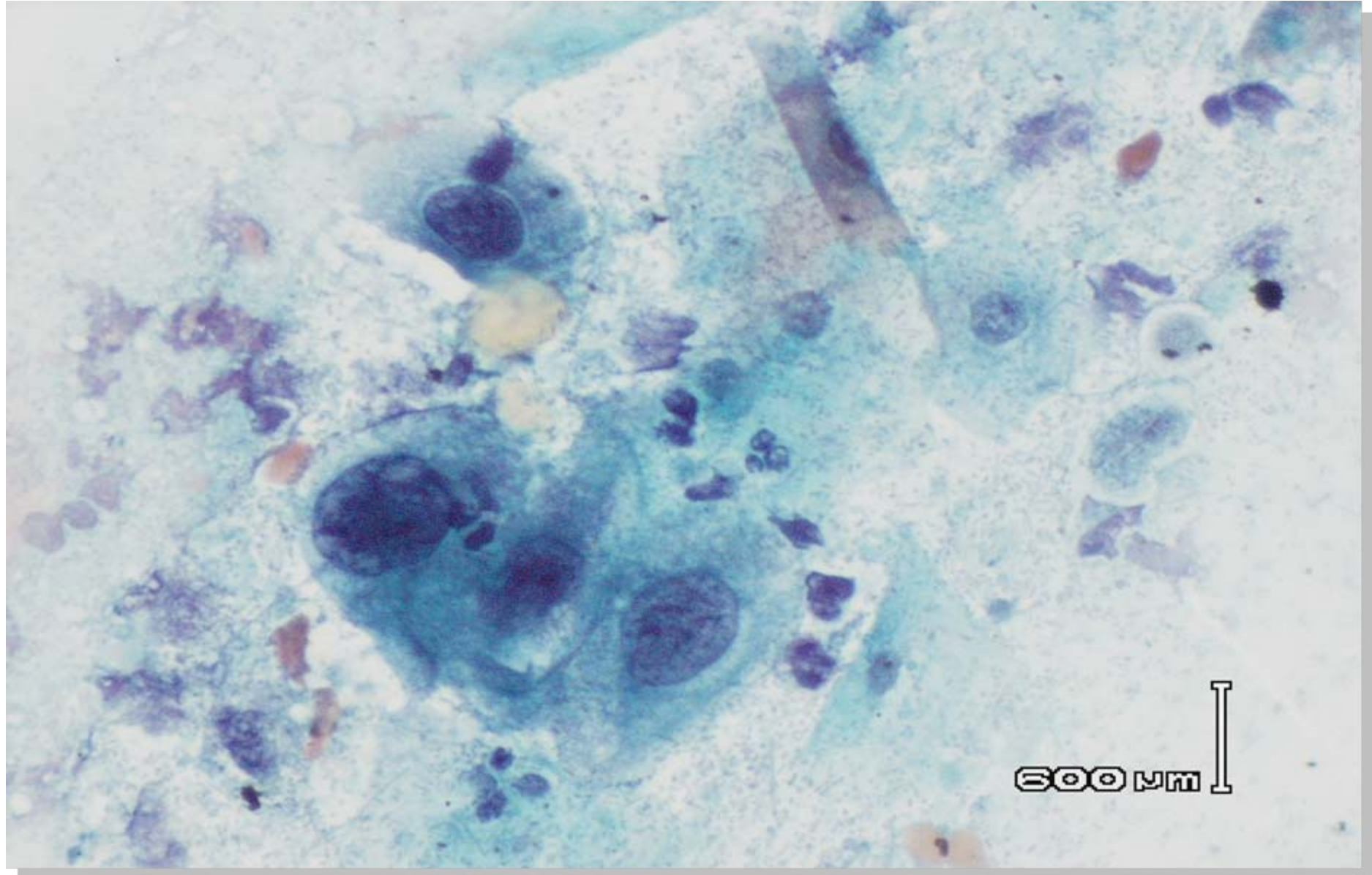
## **CASO 4**

**Idade: 42 anos**

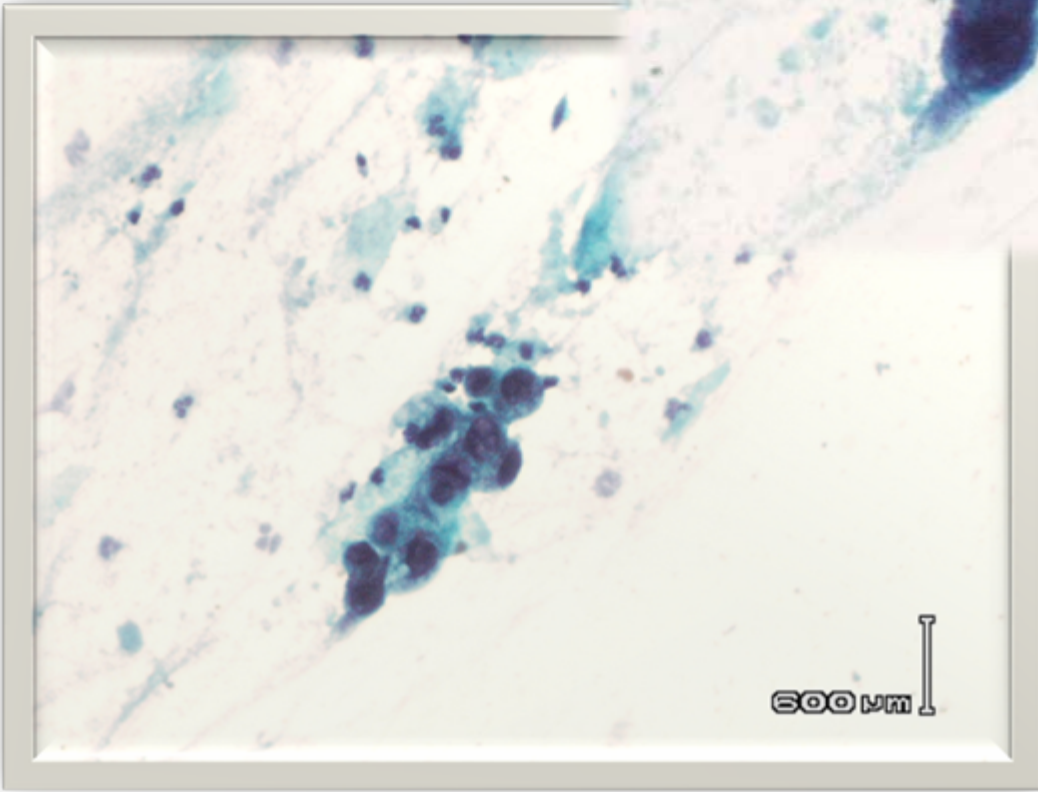
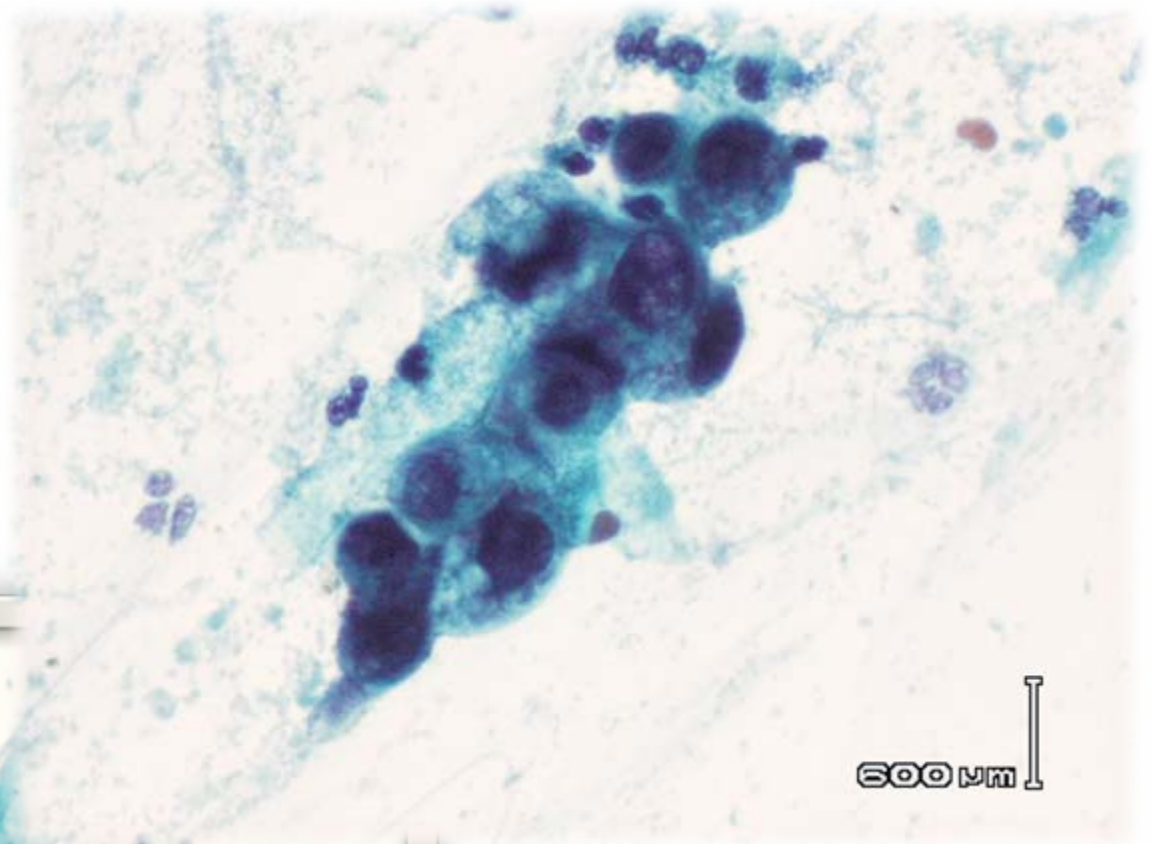
**Queixa clínica: corrimento**

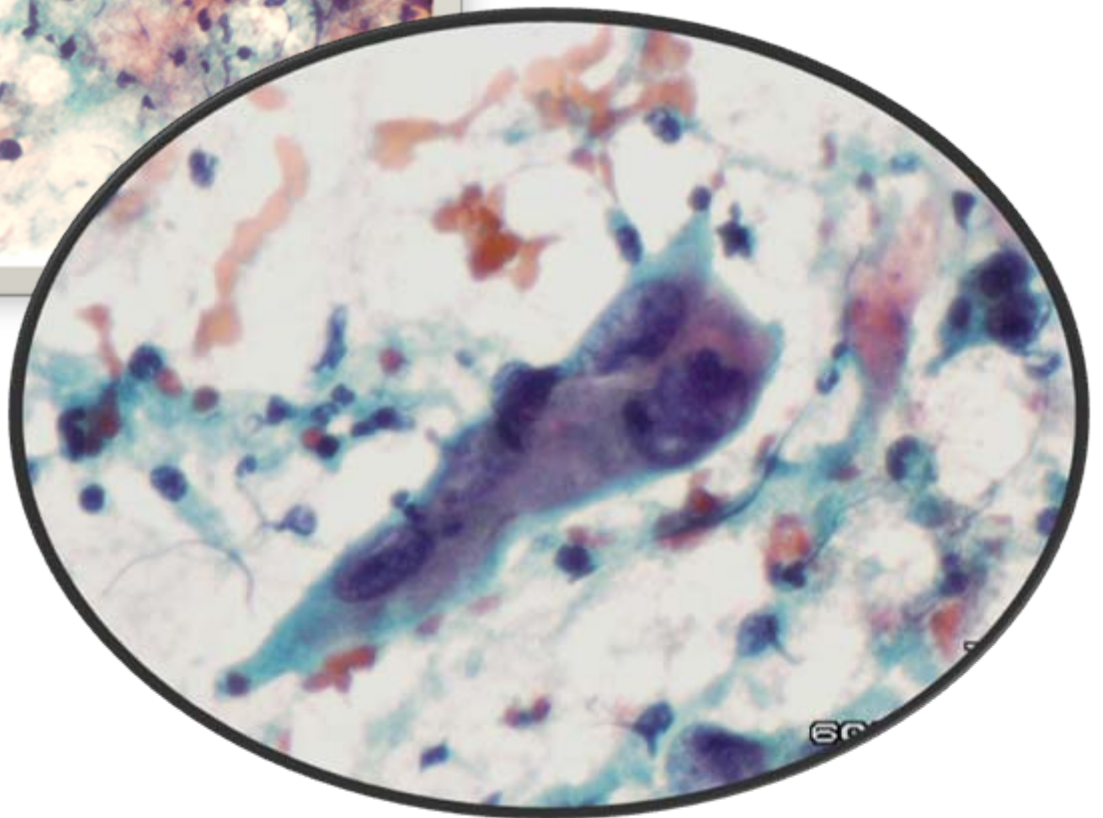
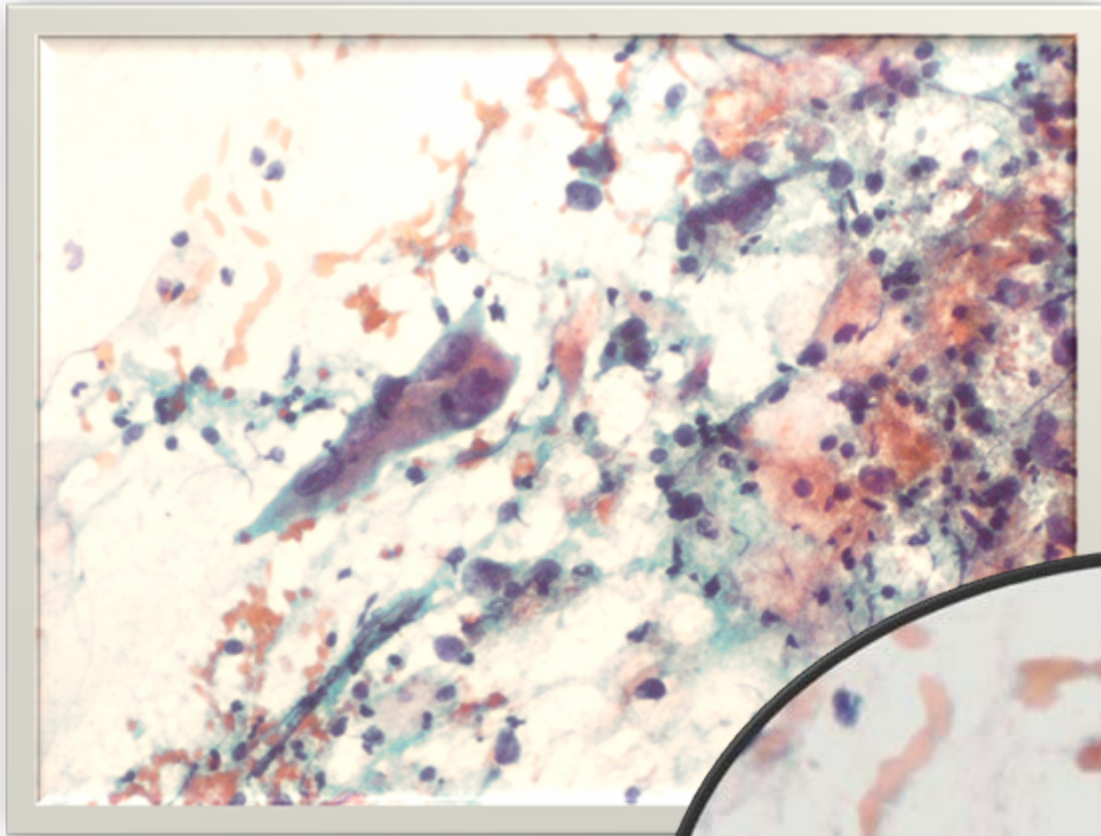
**Citologia anterior há 3 anos: ASC-US**

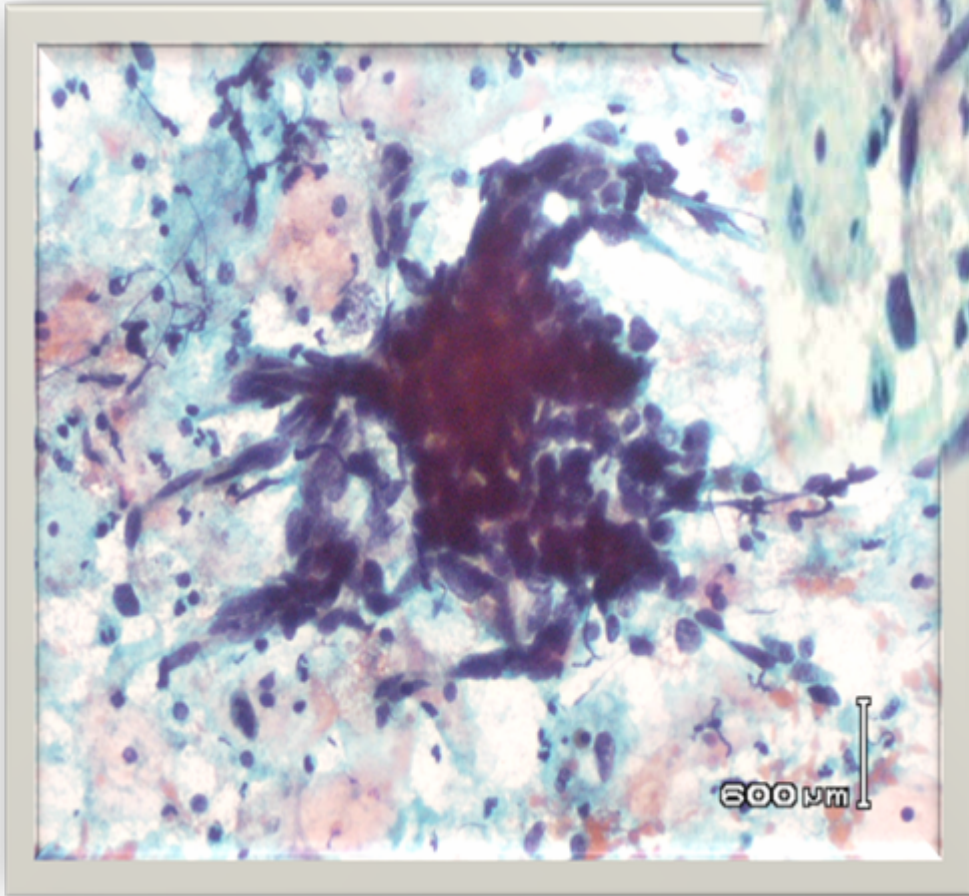
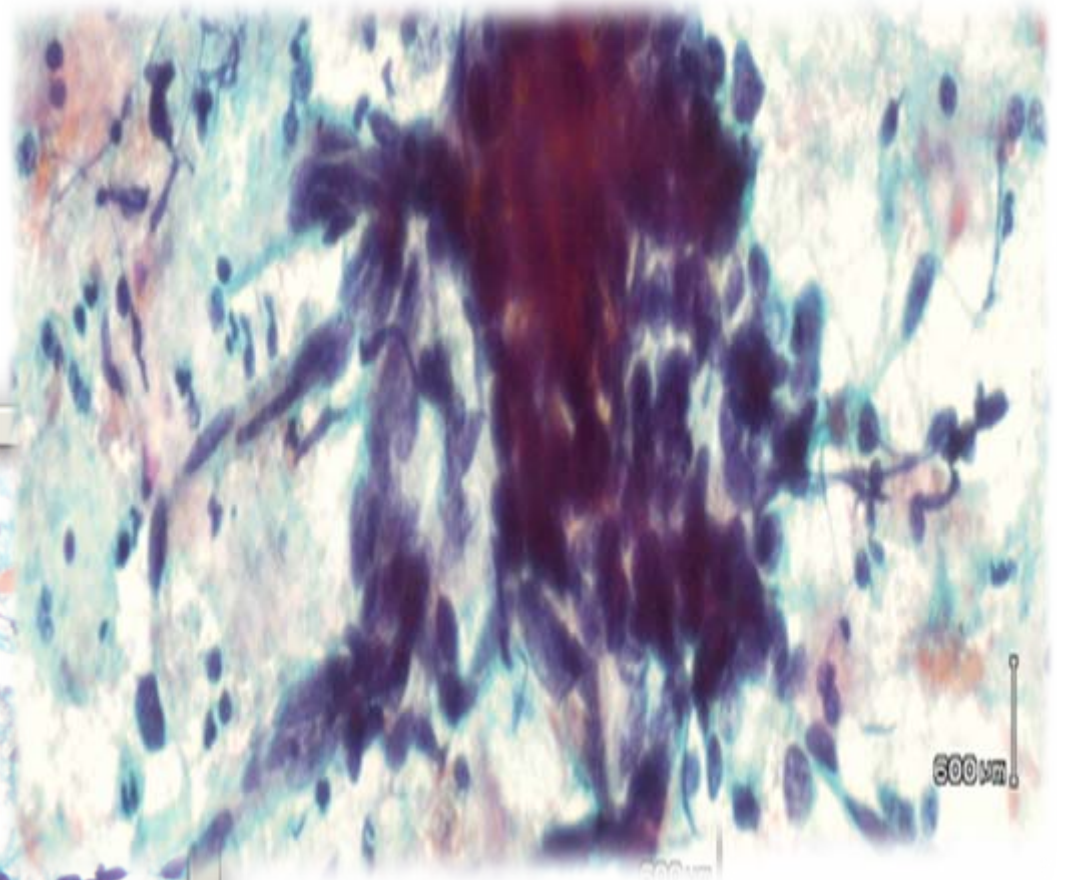




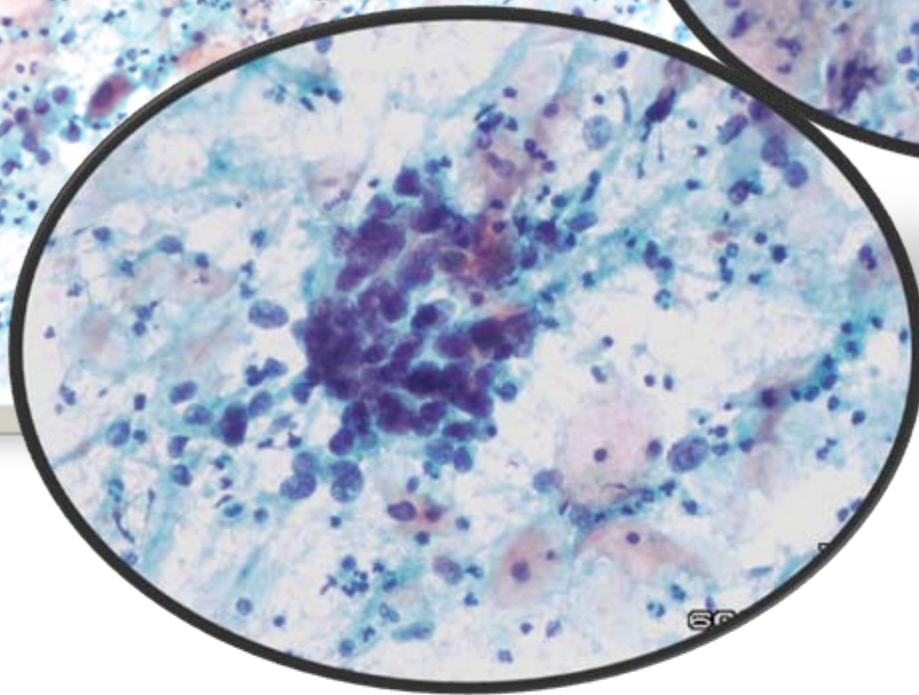
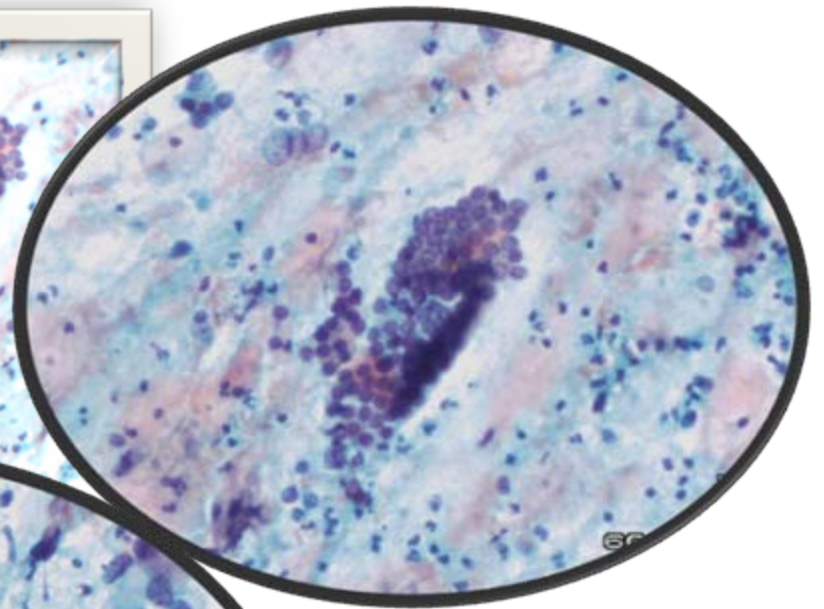
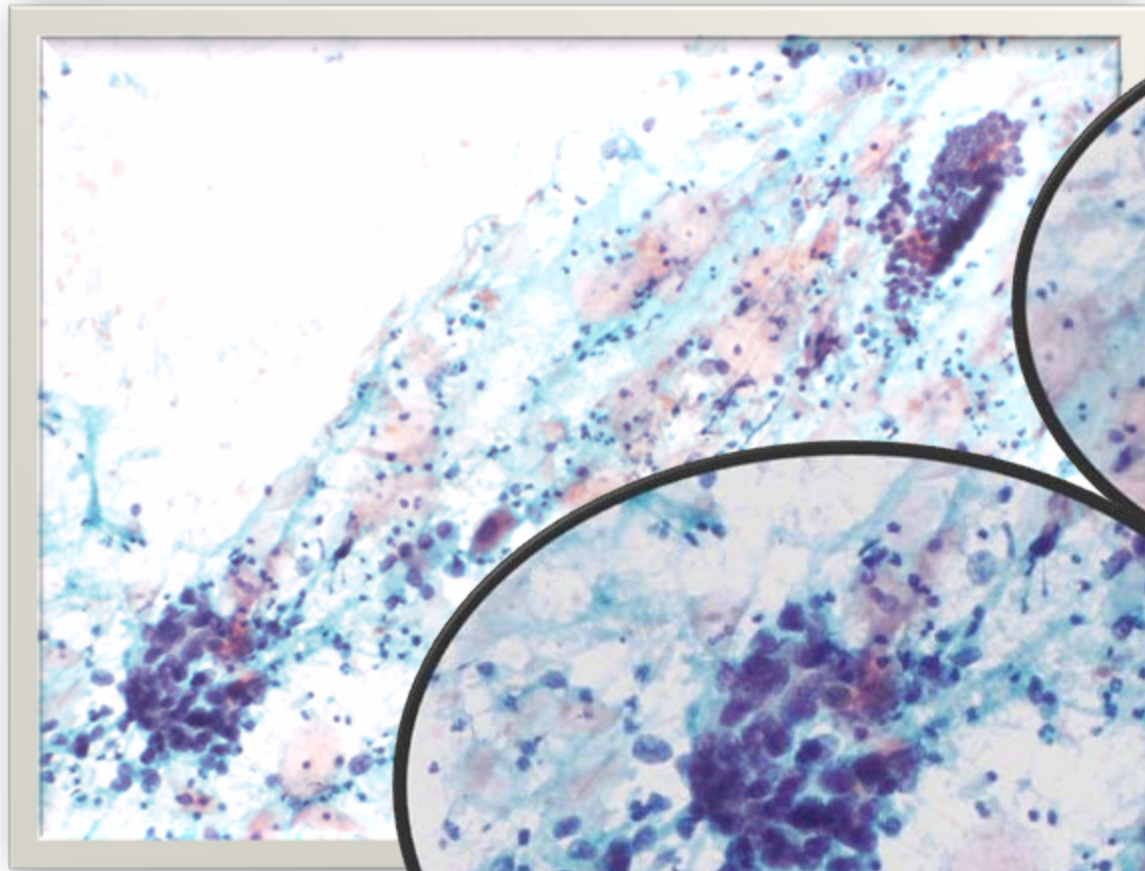
600 μm

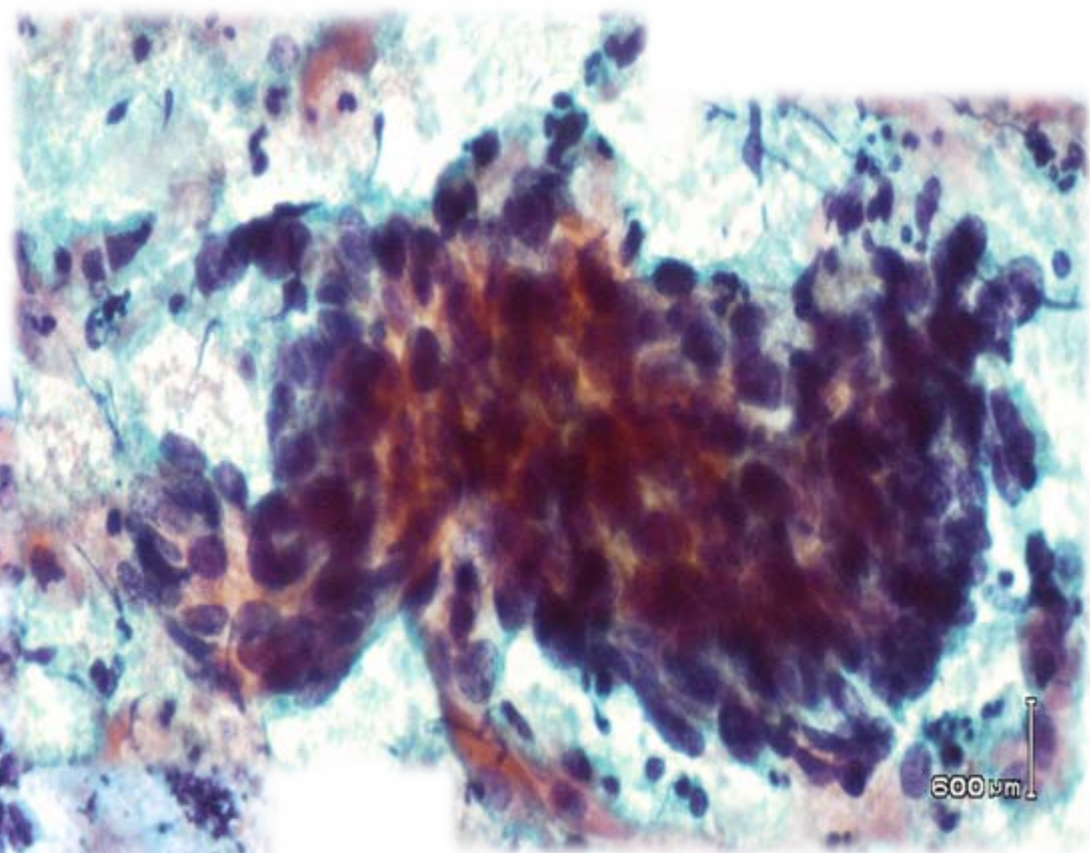
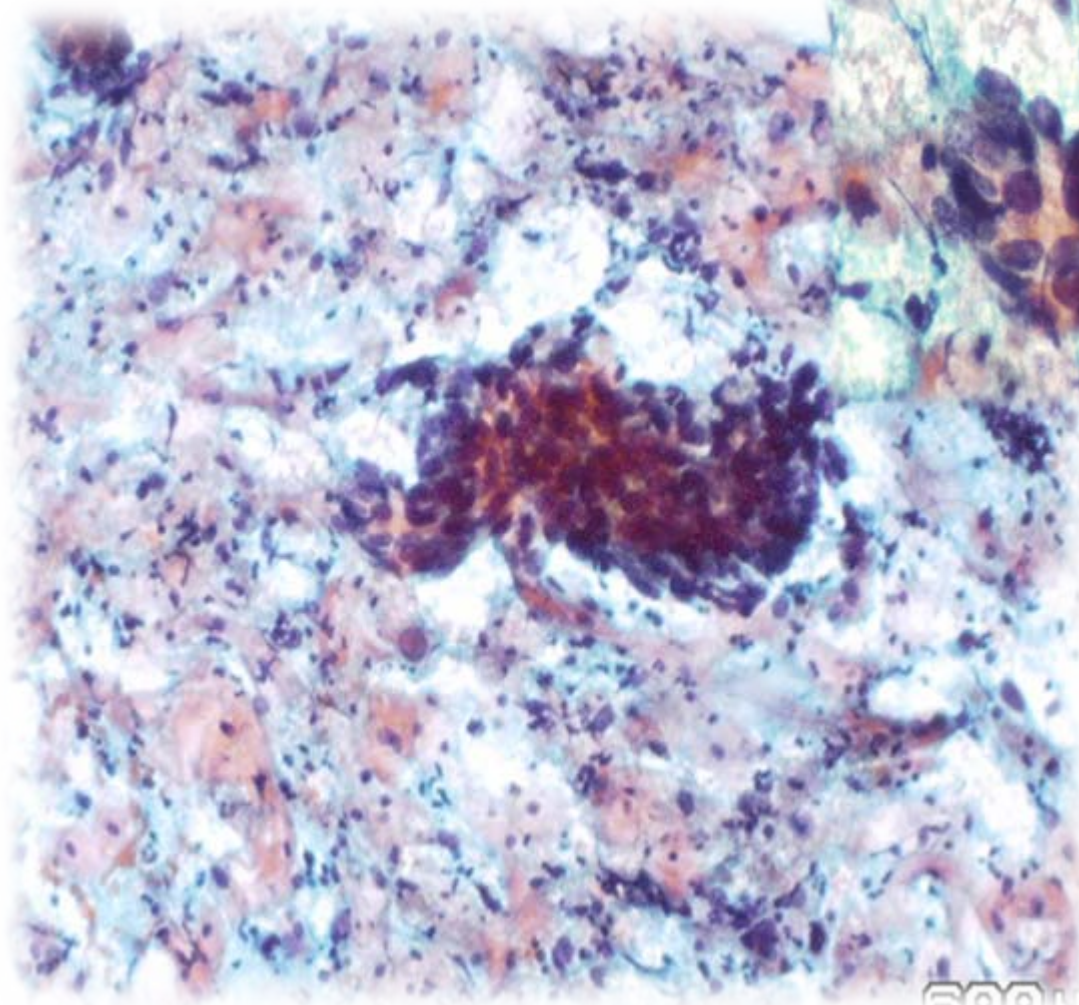


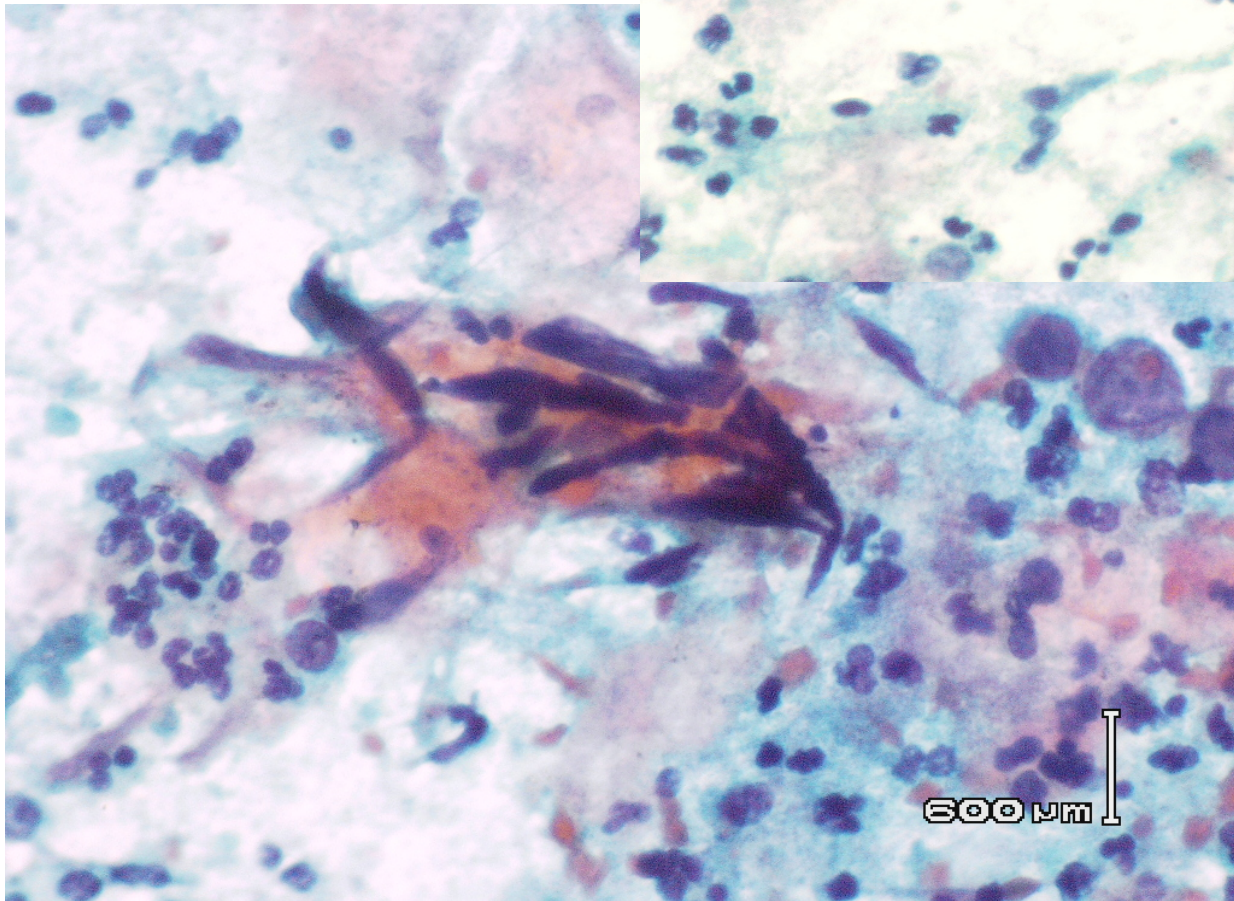
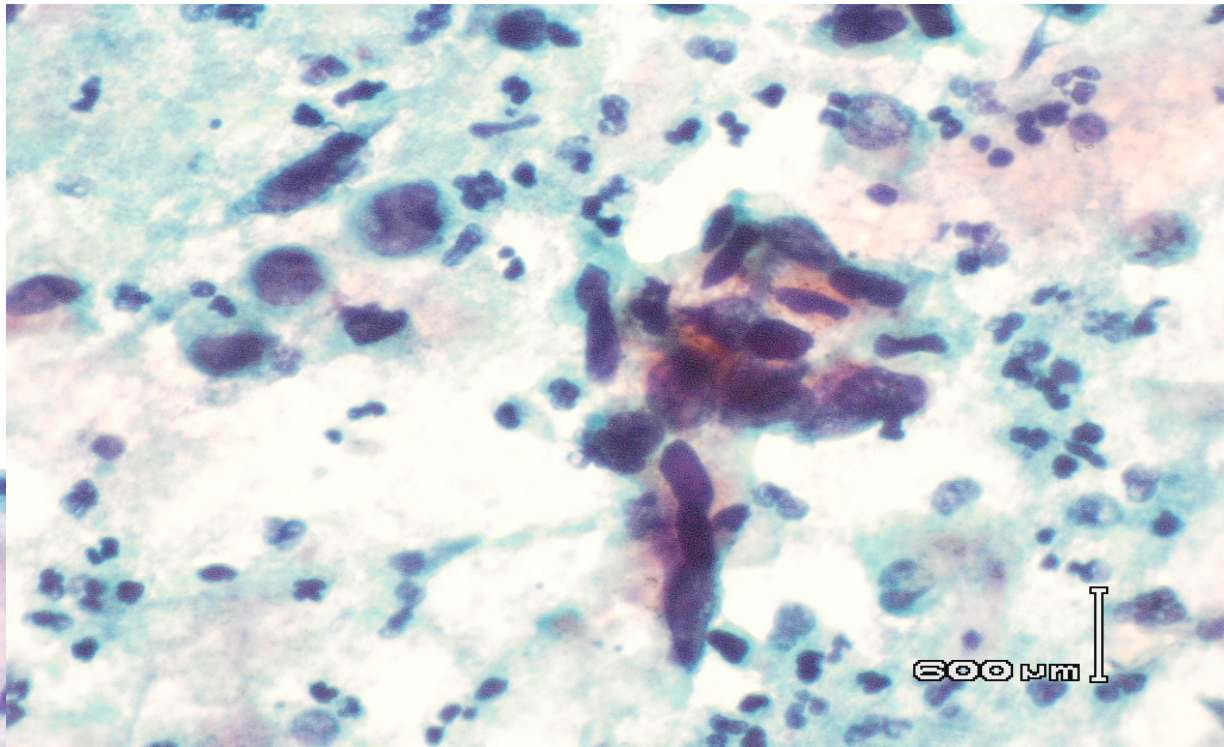


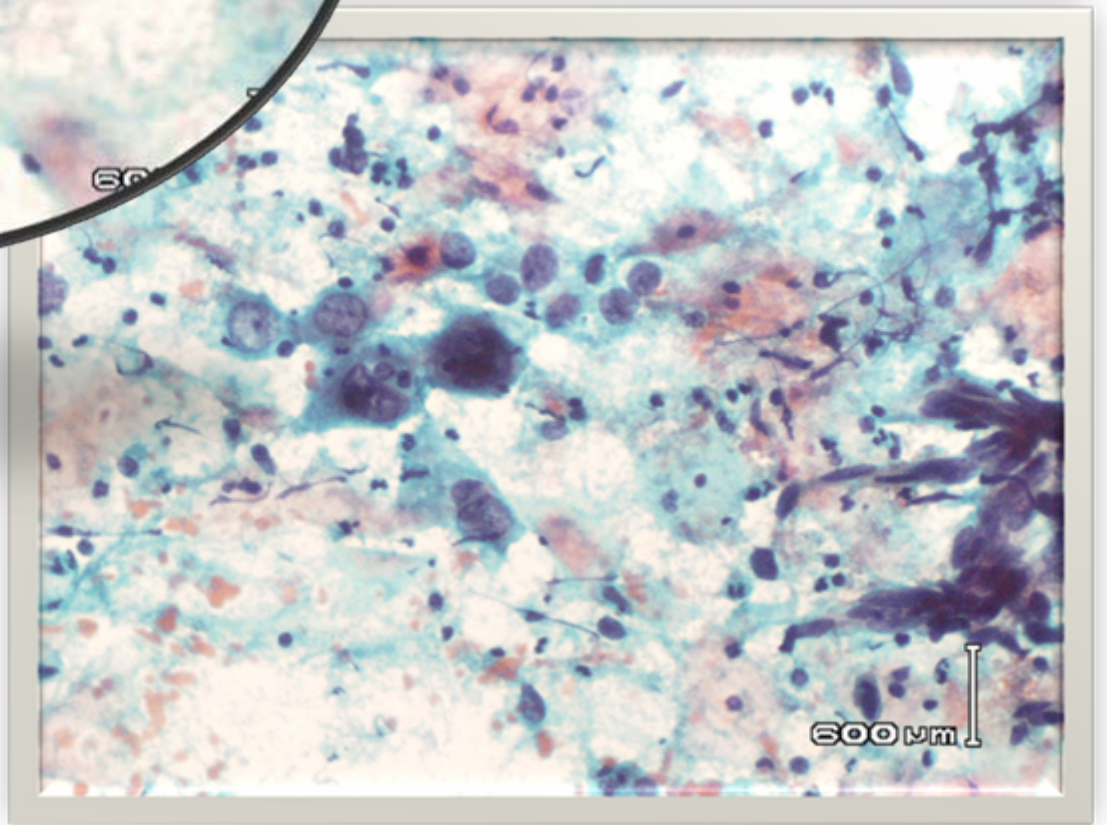
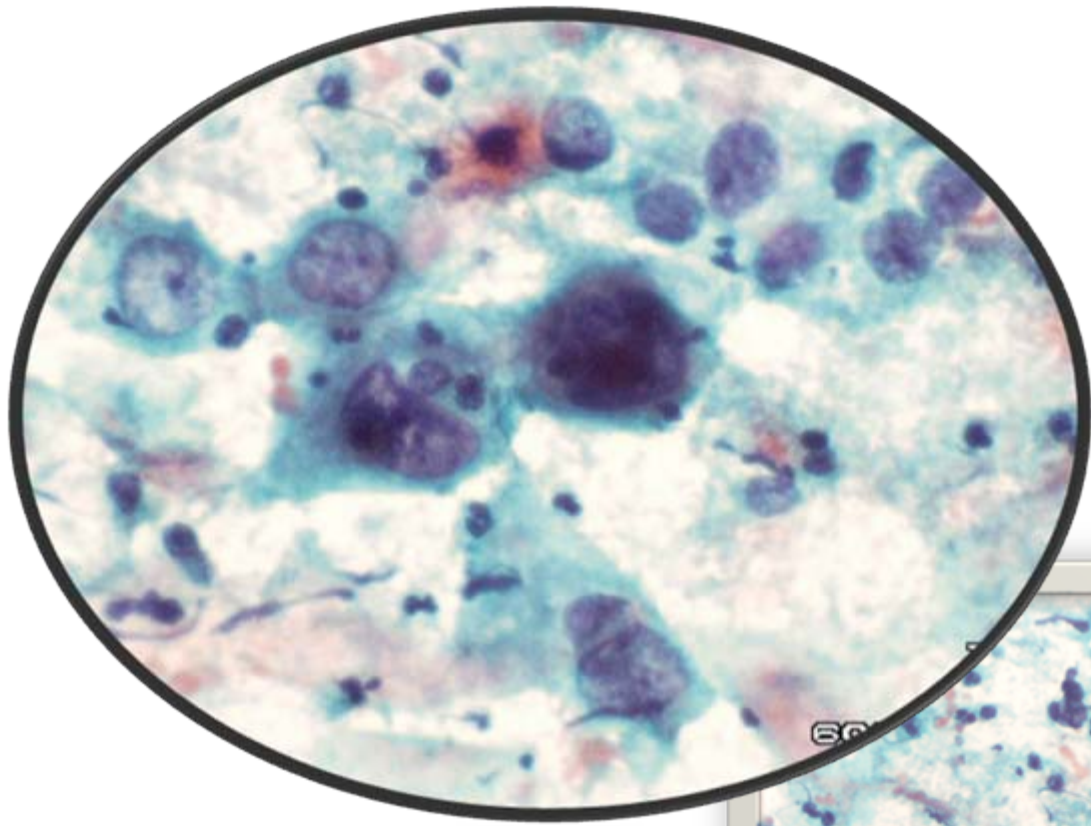









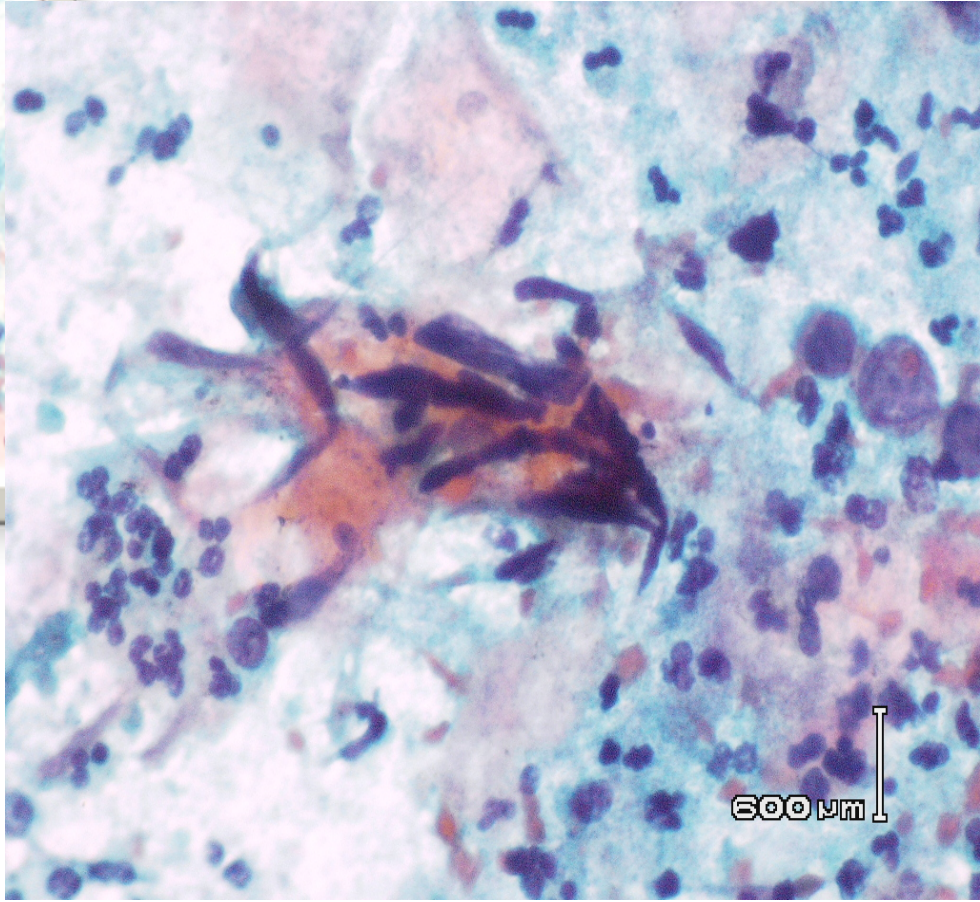
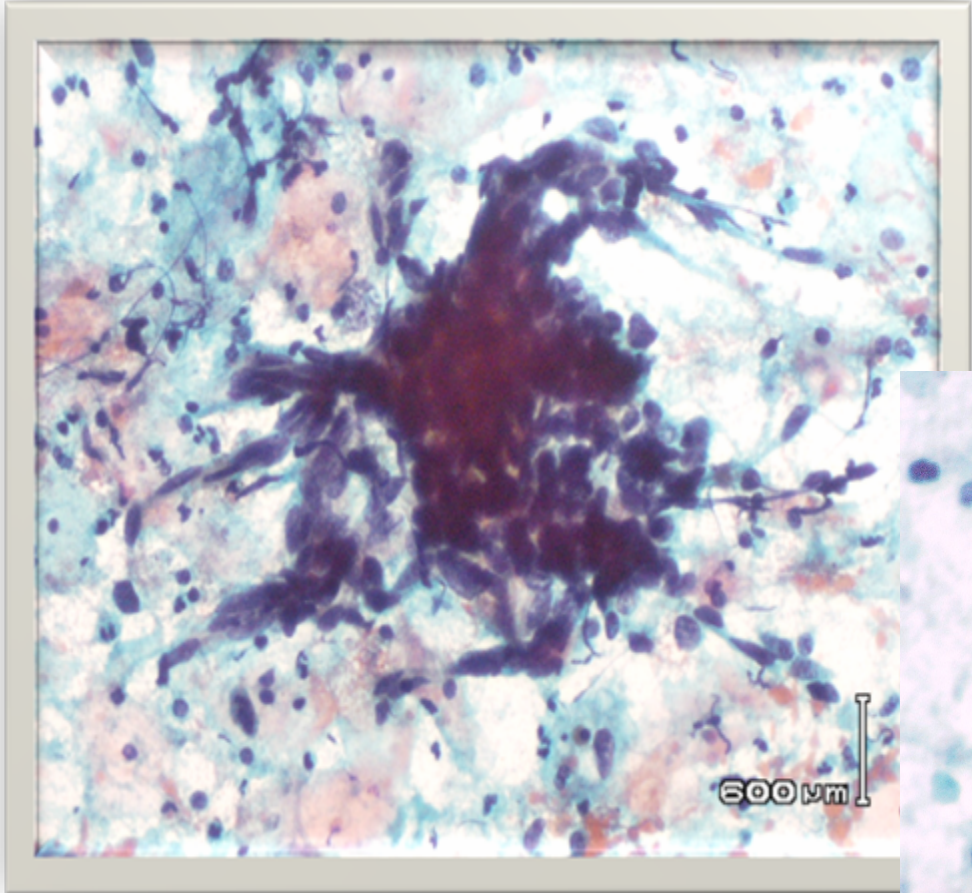




# Diagnóstico Citopatológico

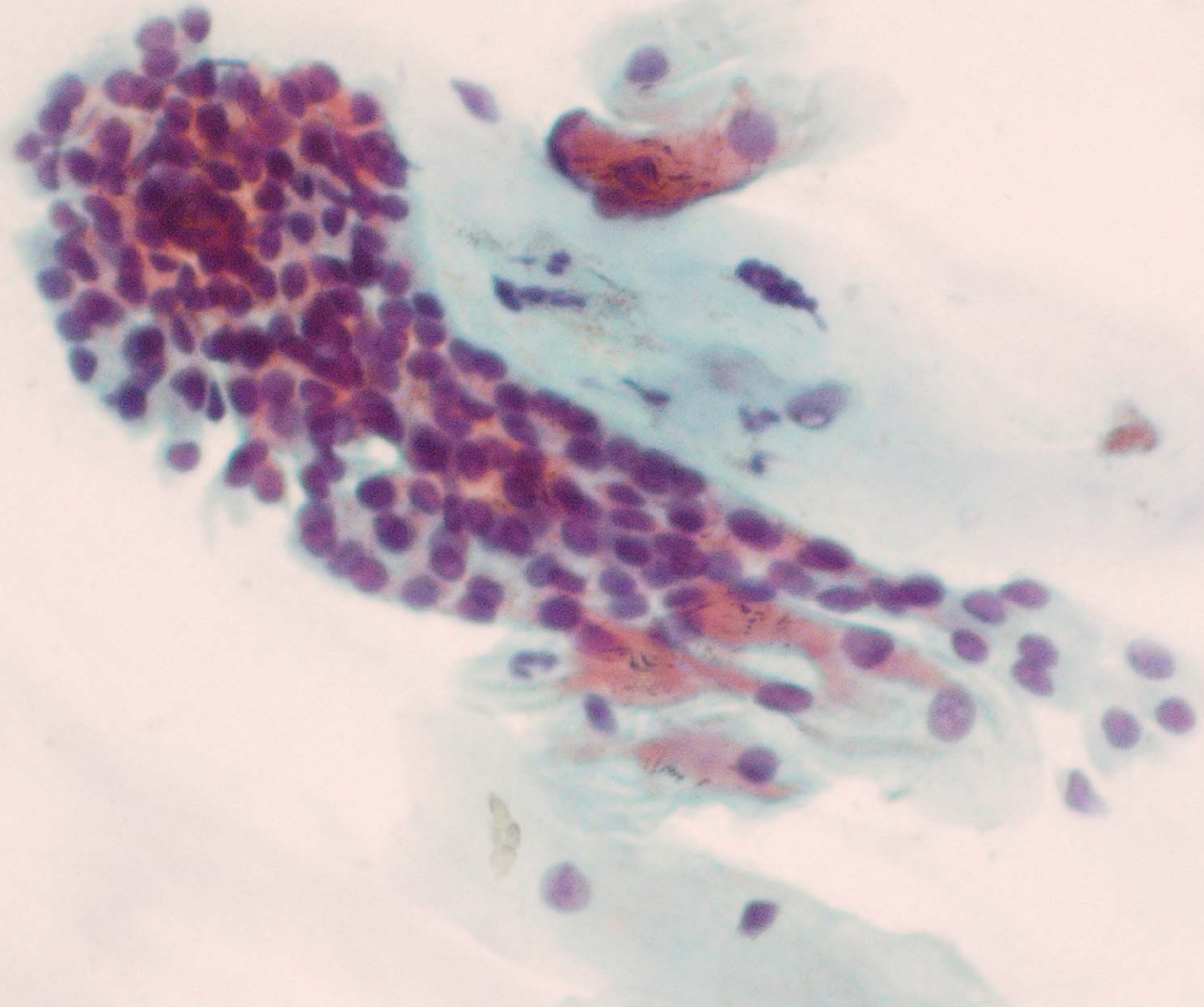


**Carcinoma + AGC-H**

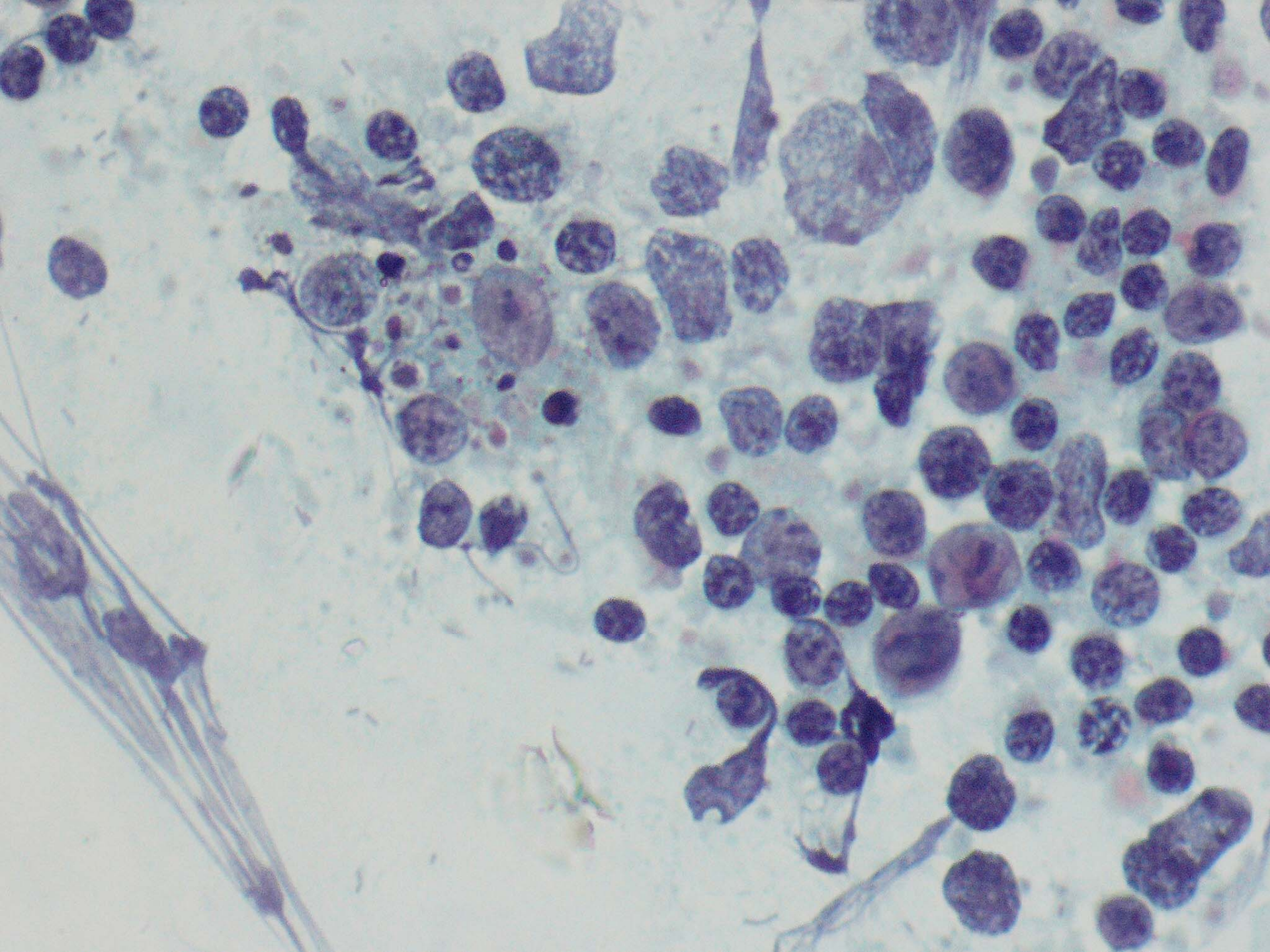


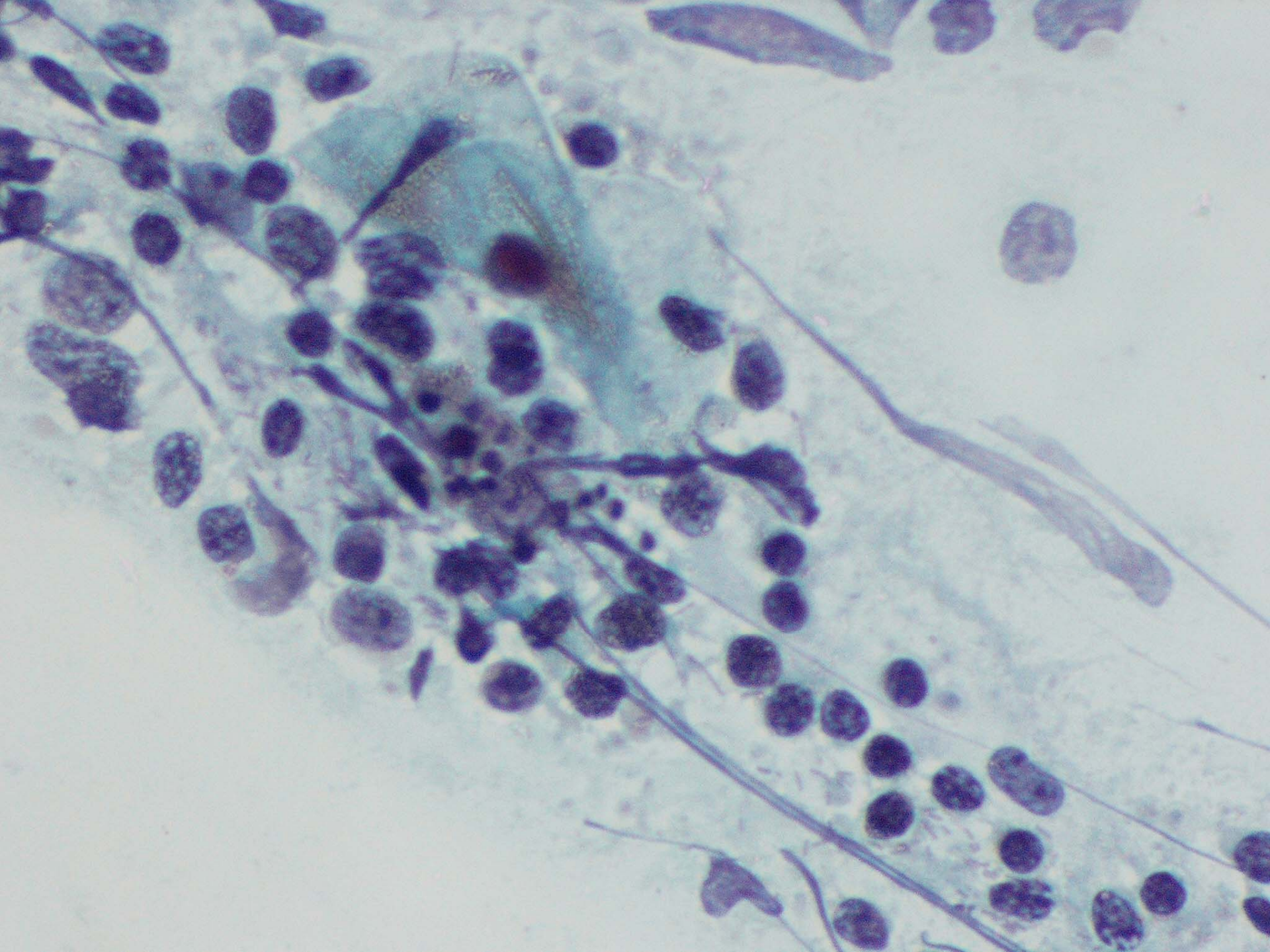
## **CASO 5**

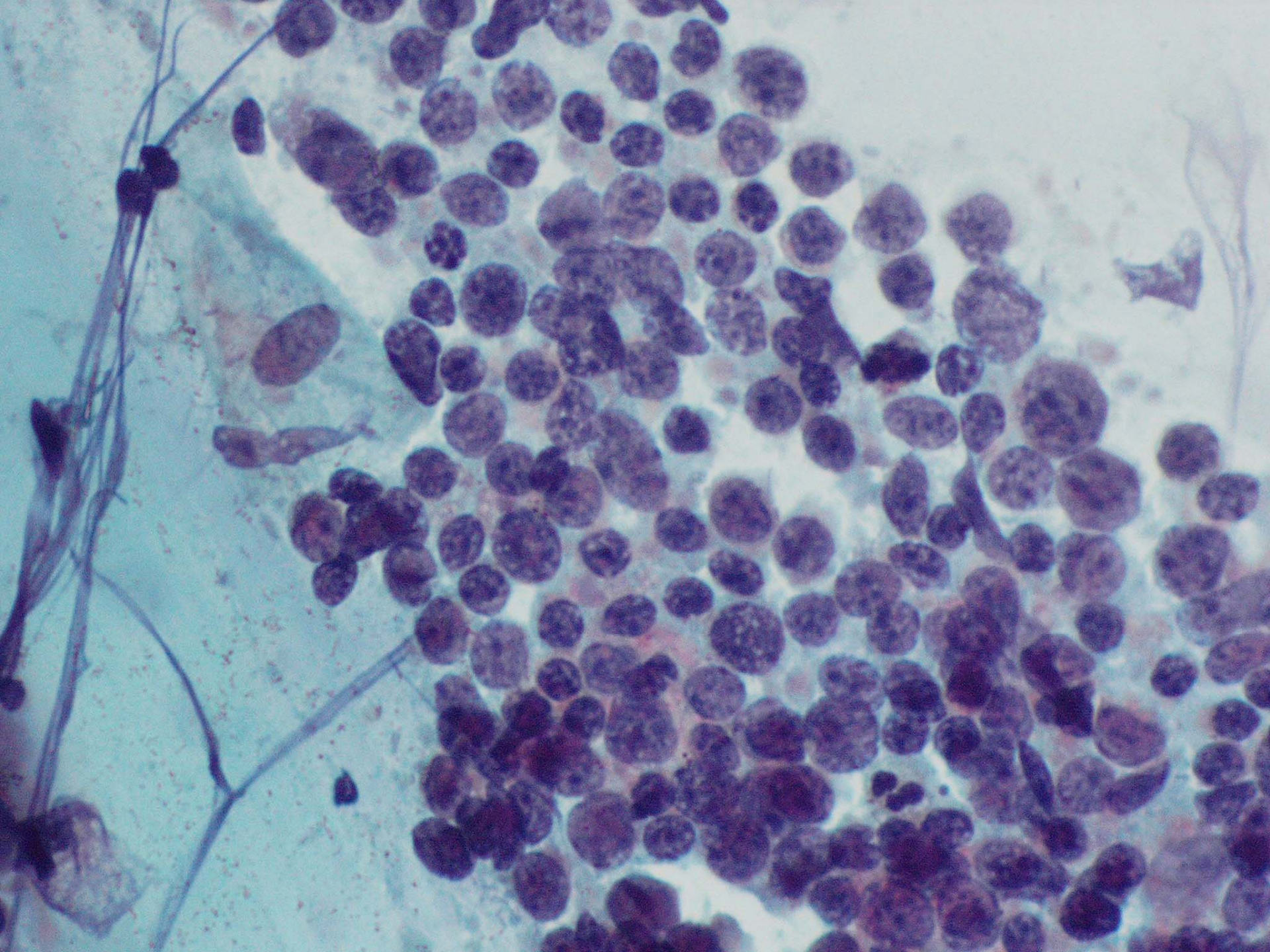
**Paciente de 57 anos  
Menopausa há 6 anos**

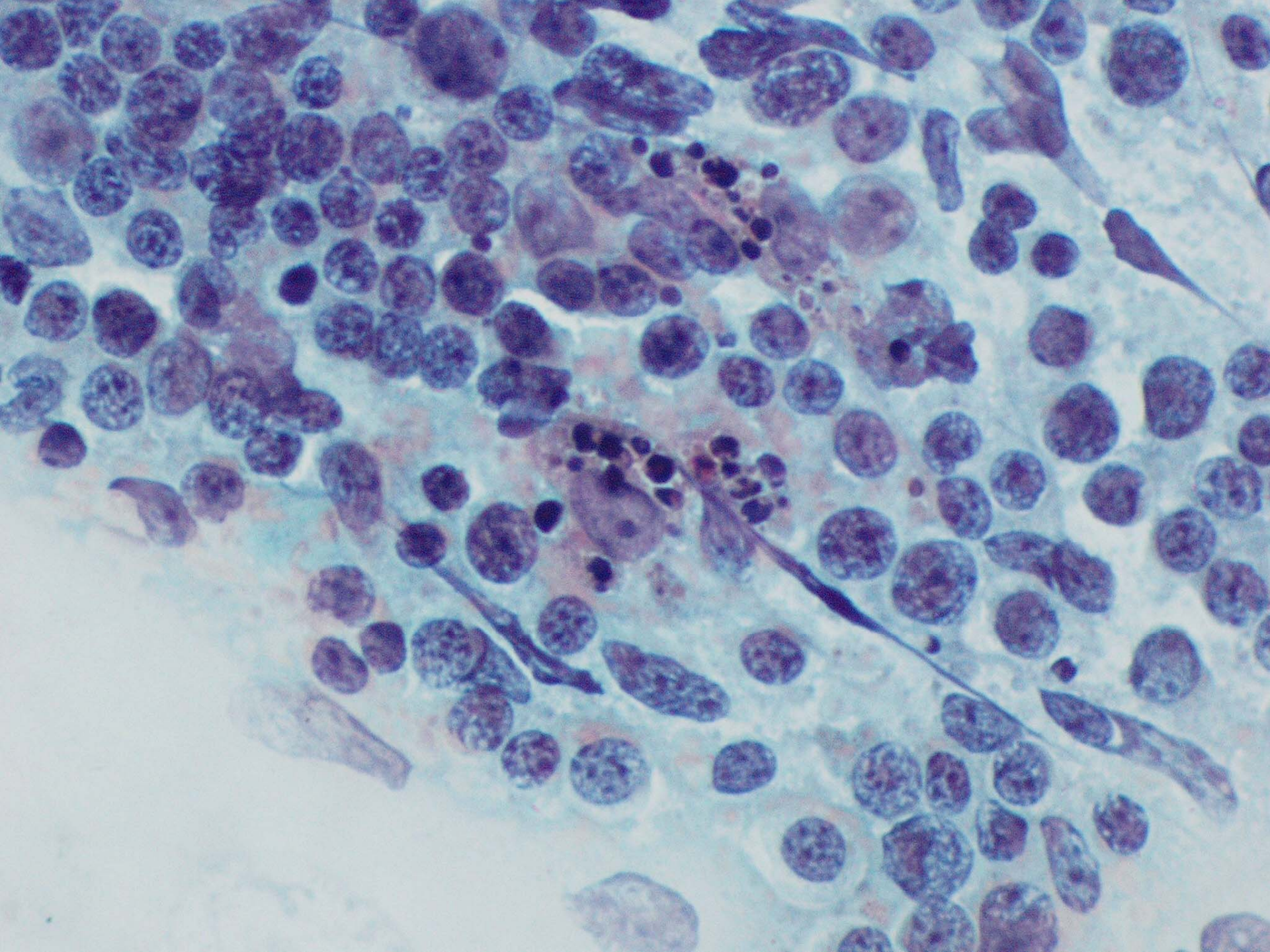


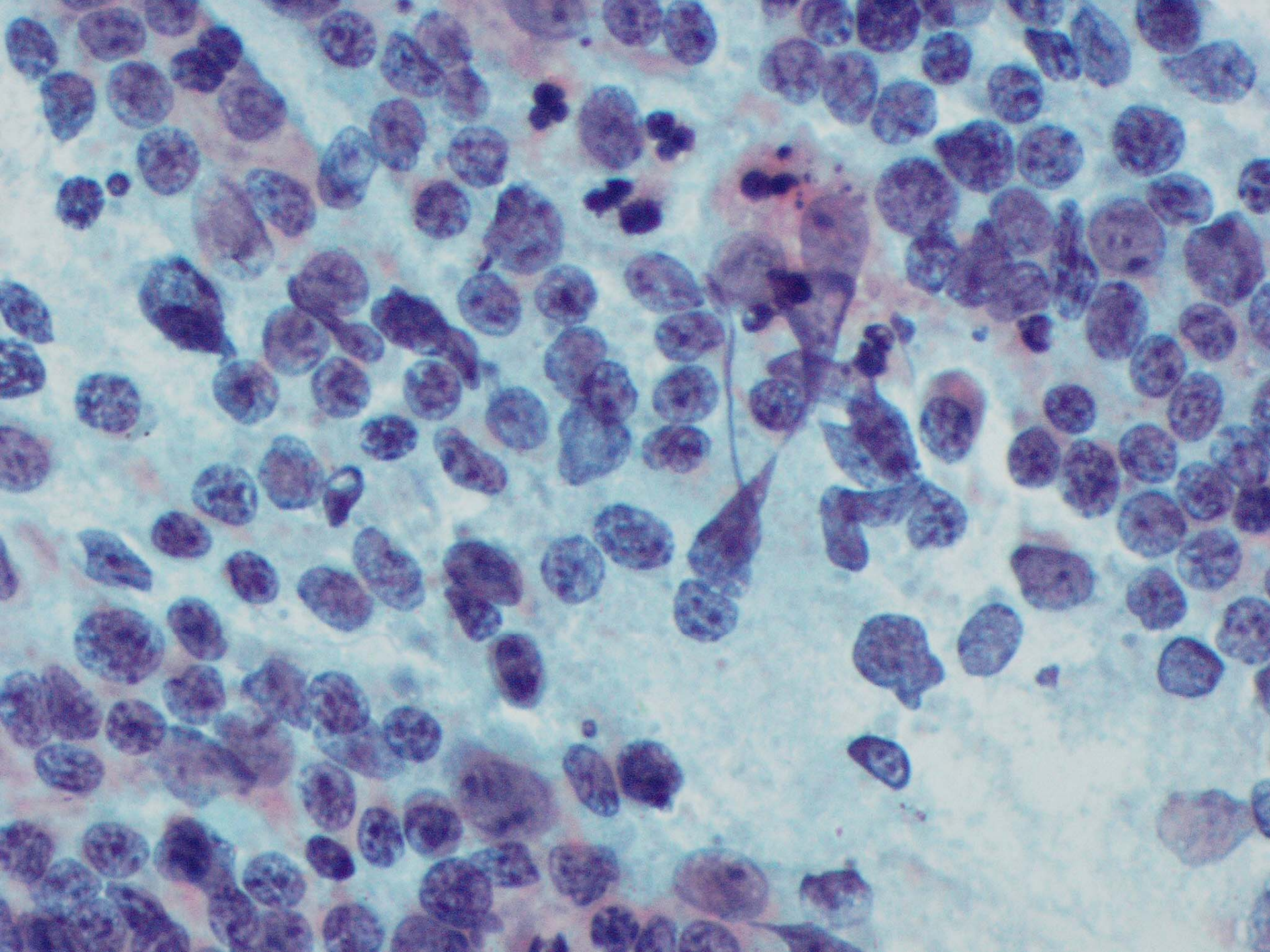


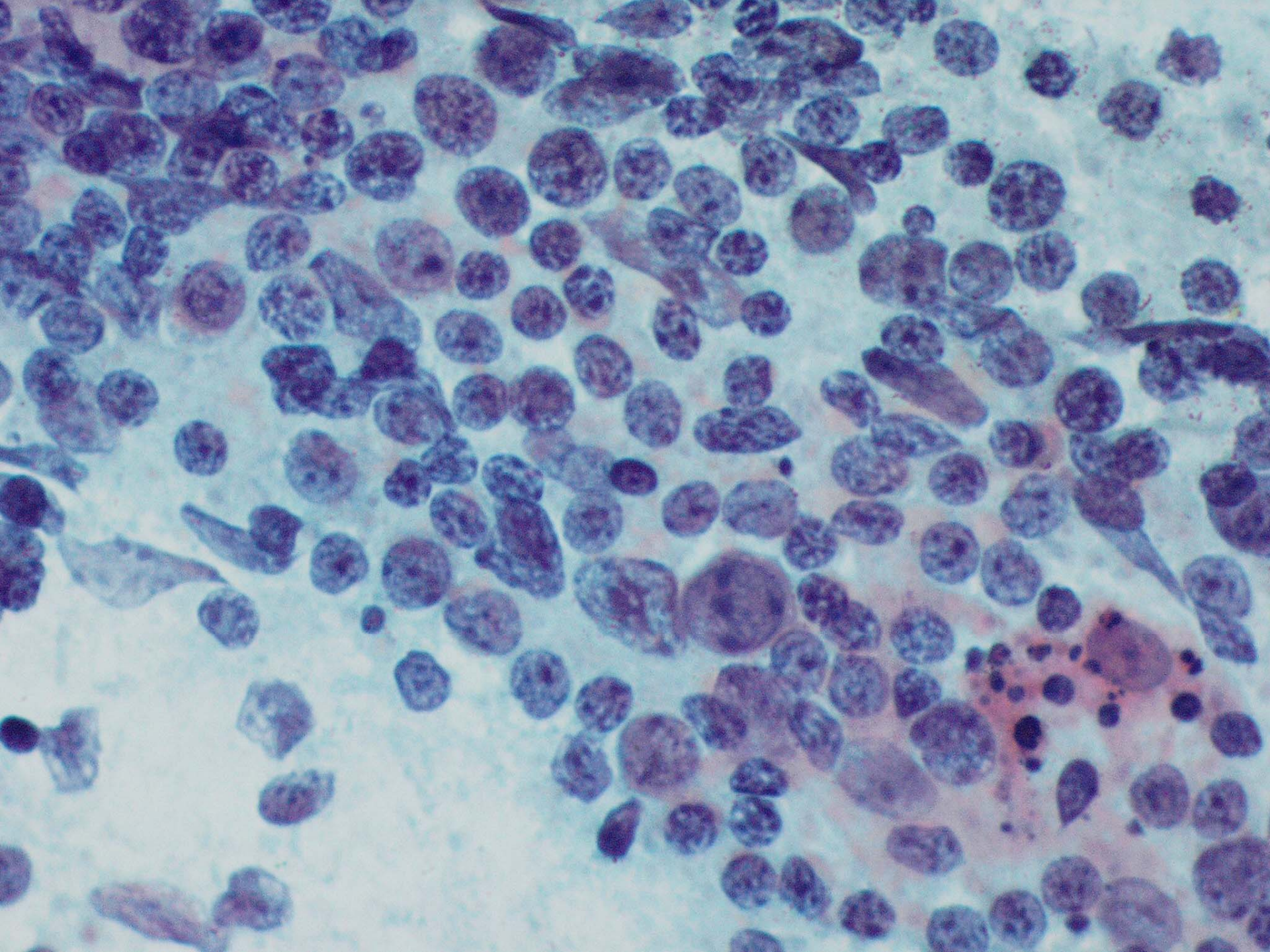


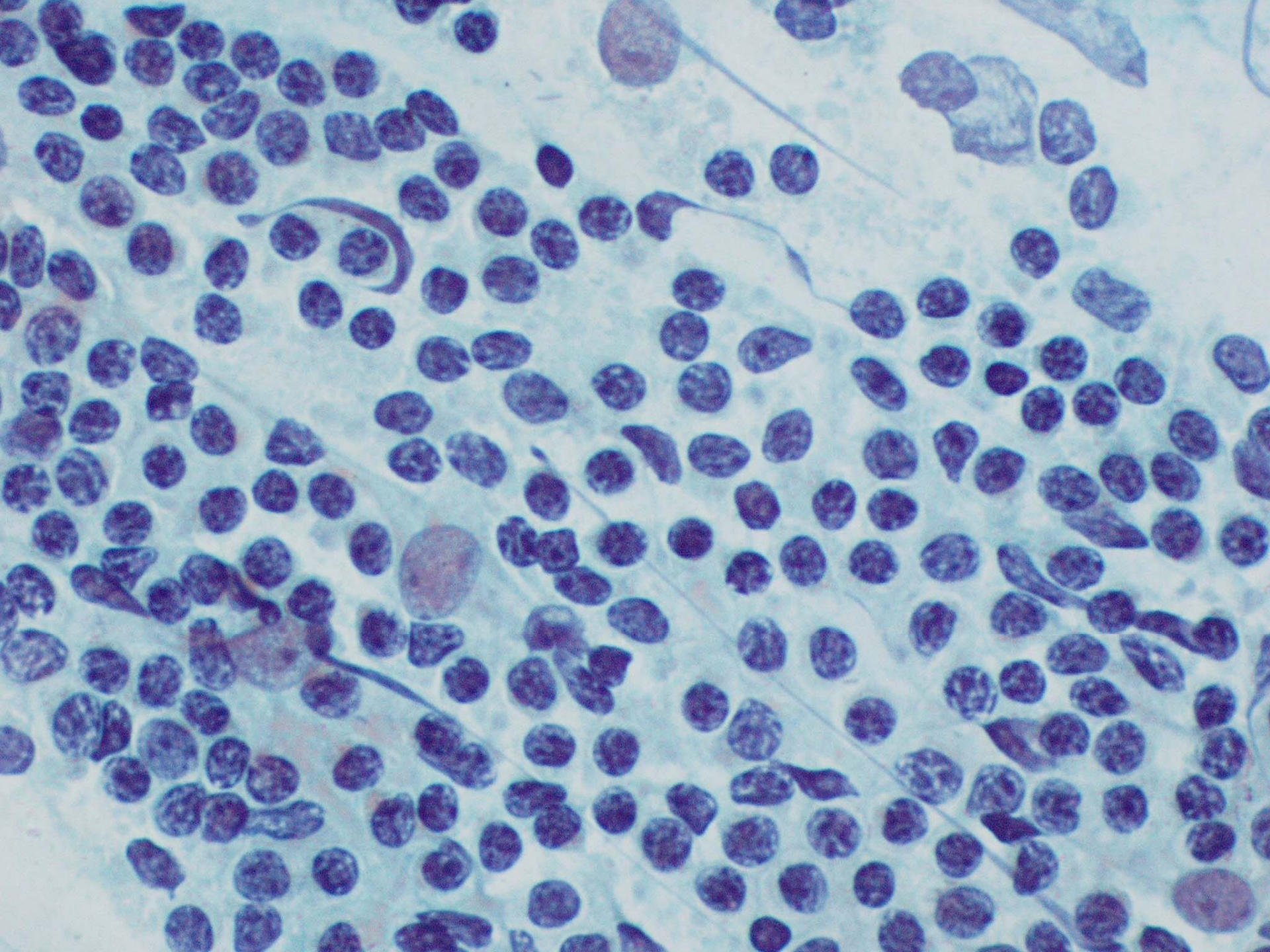











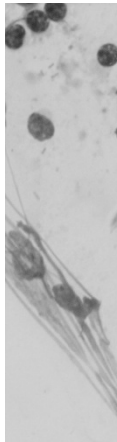
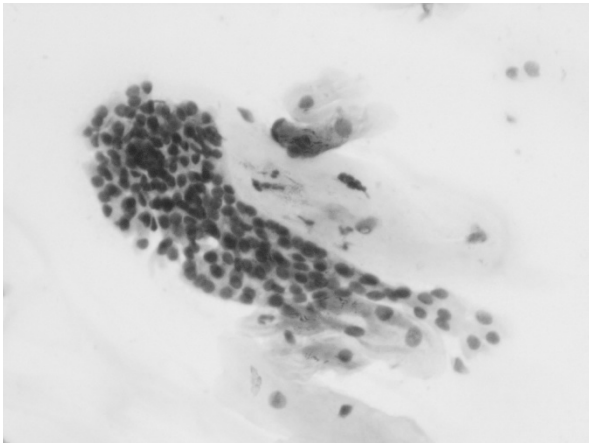
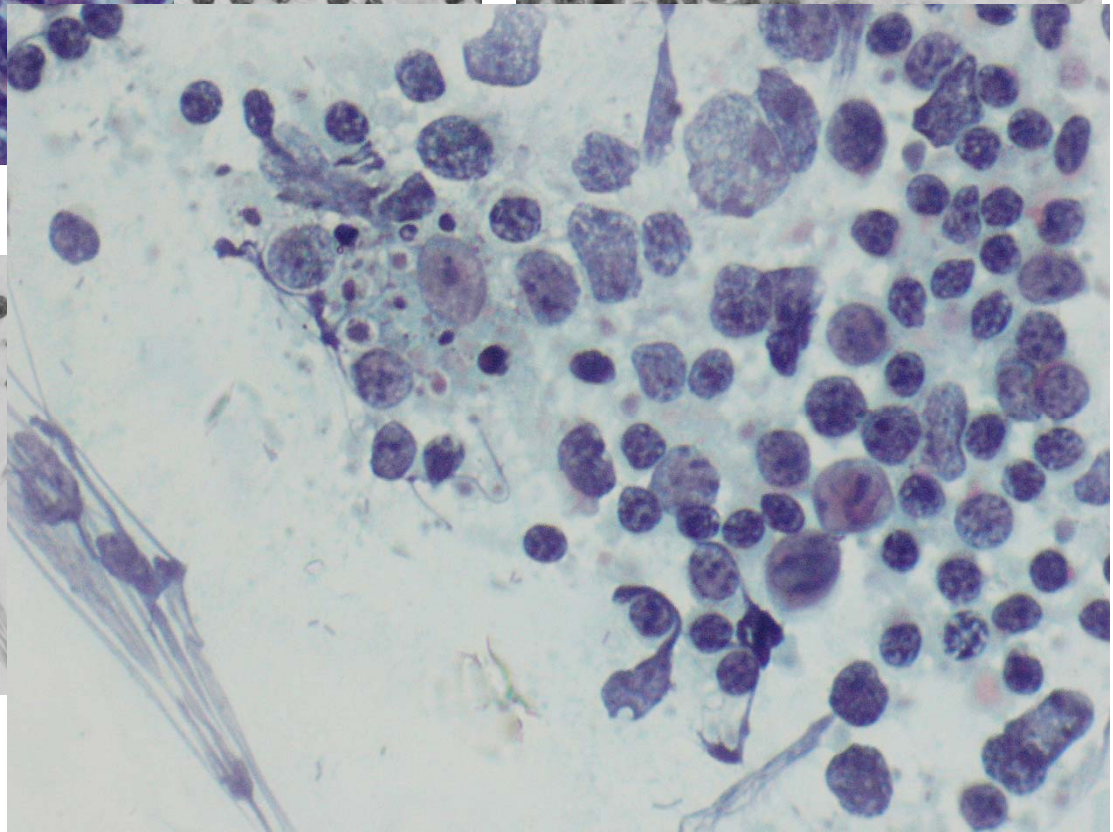
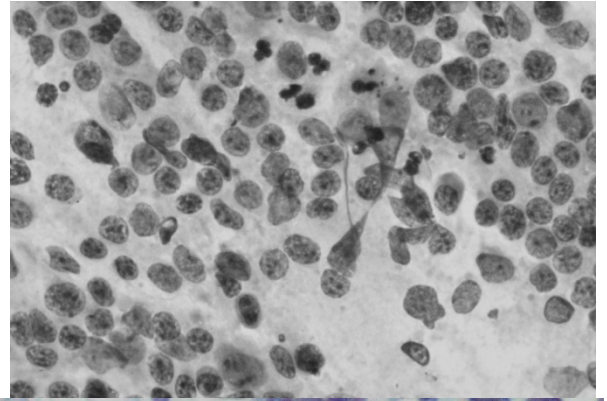
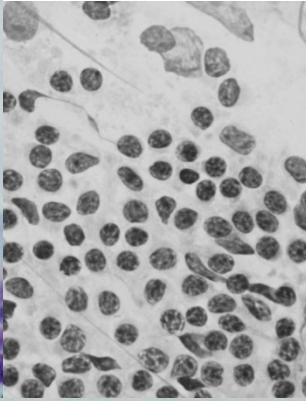
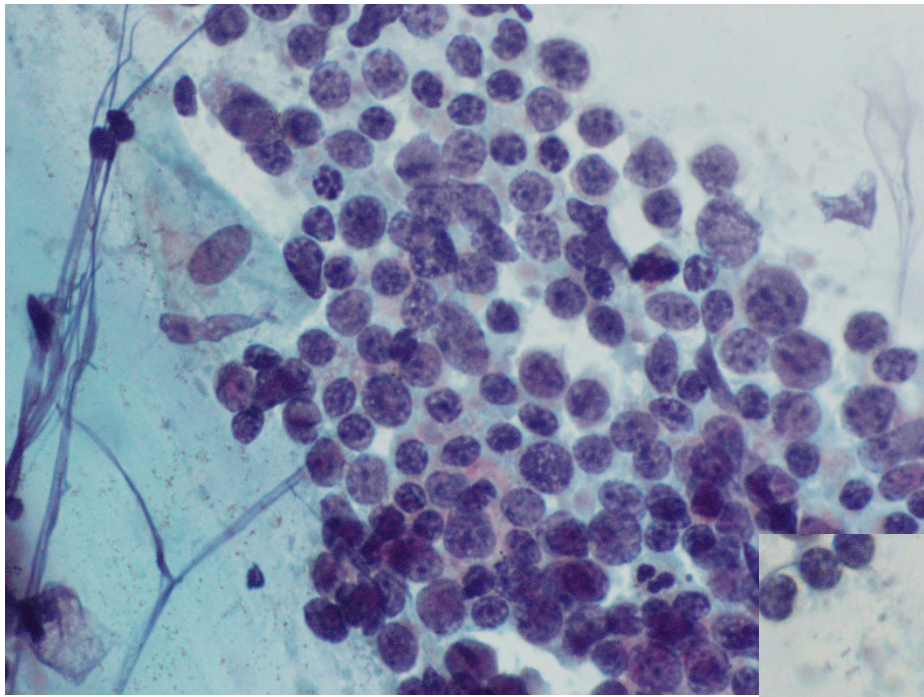


# Diagnóstico Citopatológico



**Cervicite Folicular**

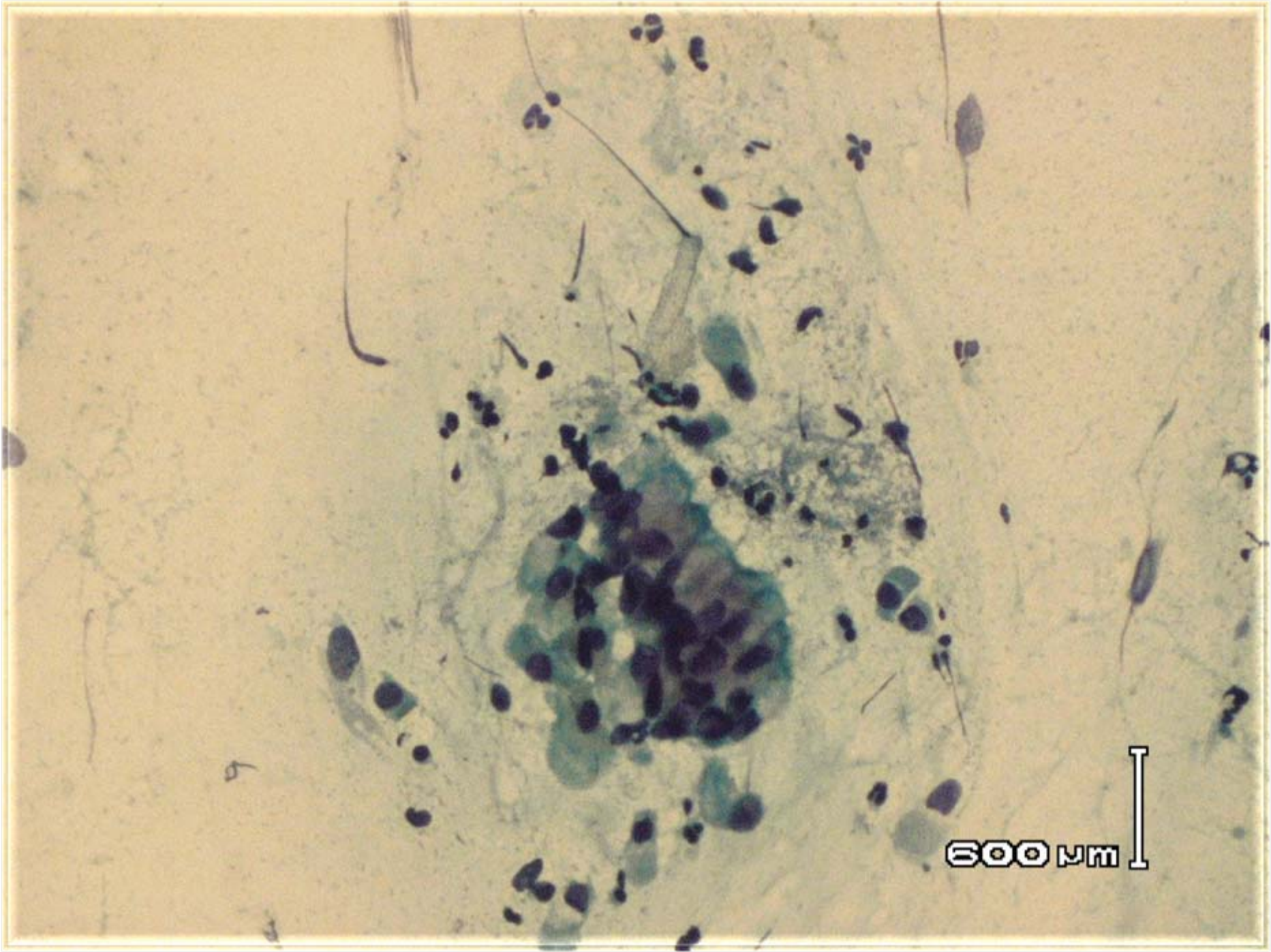




## Caso 6

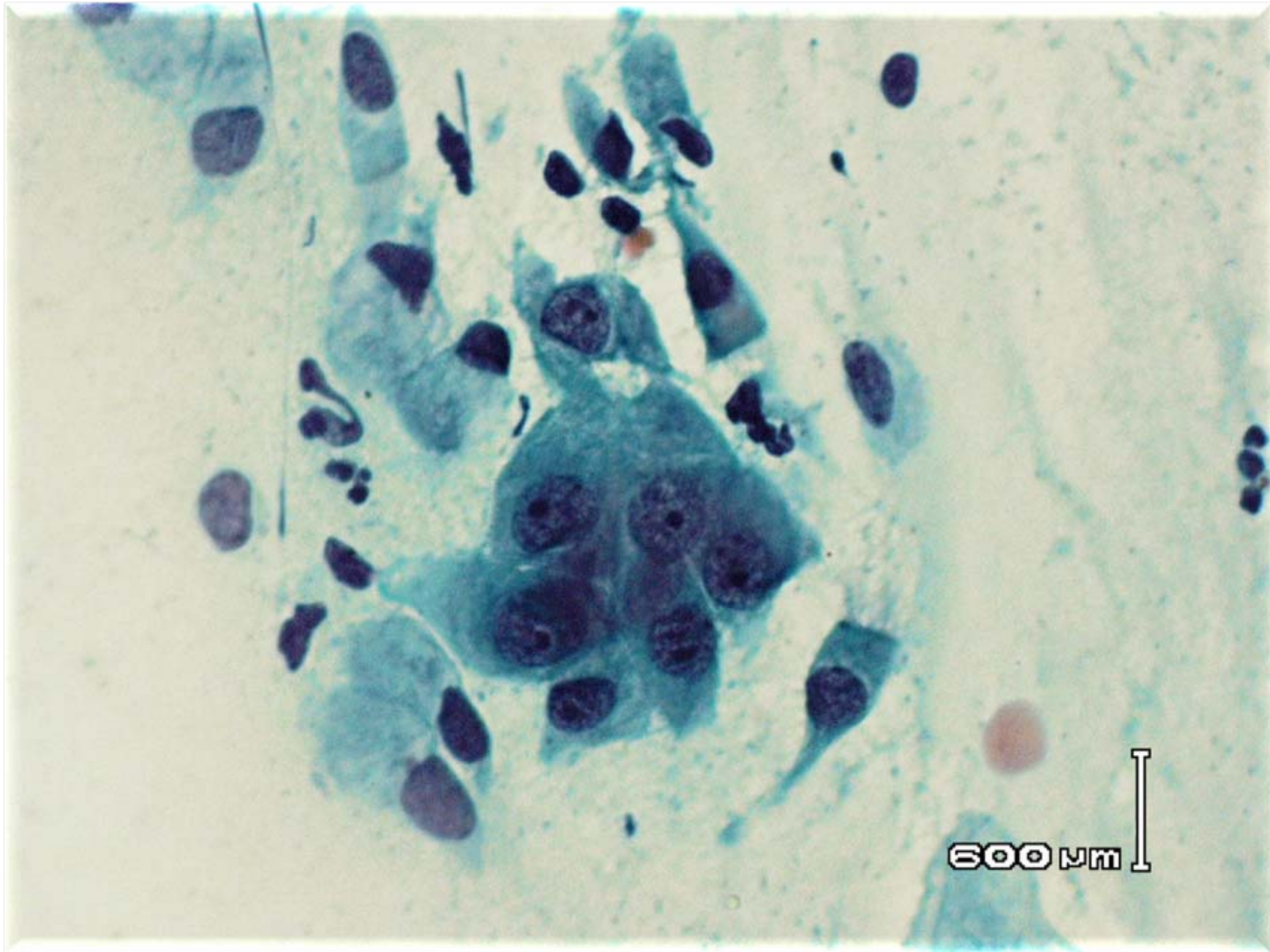
**Idade: 29 anos**

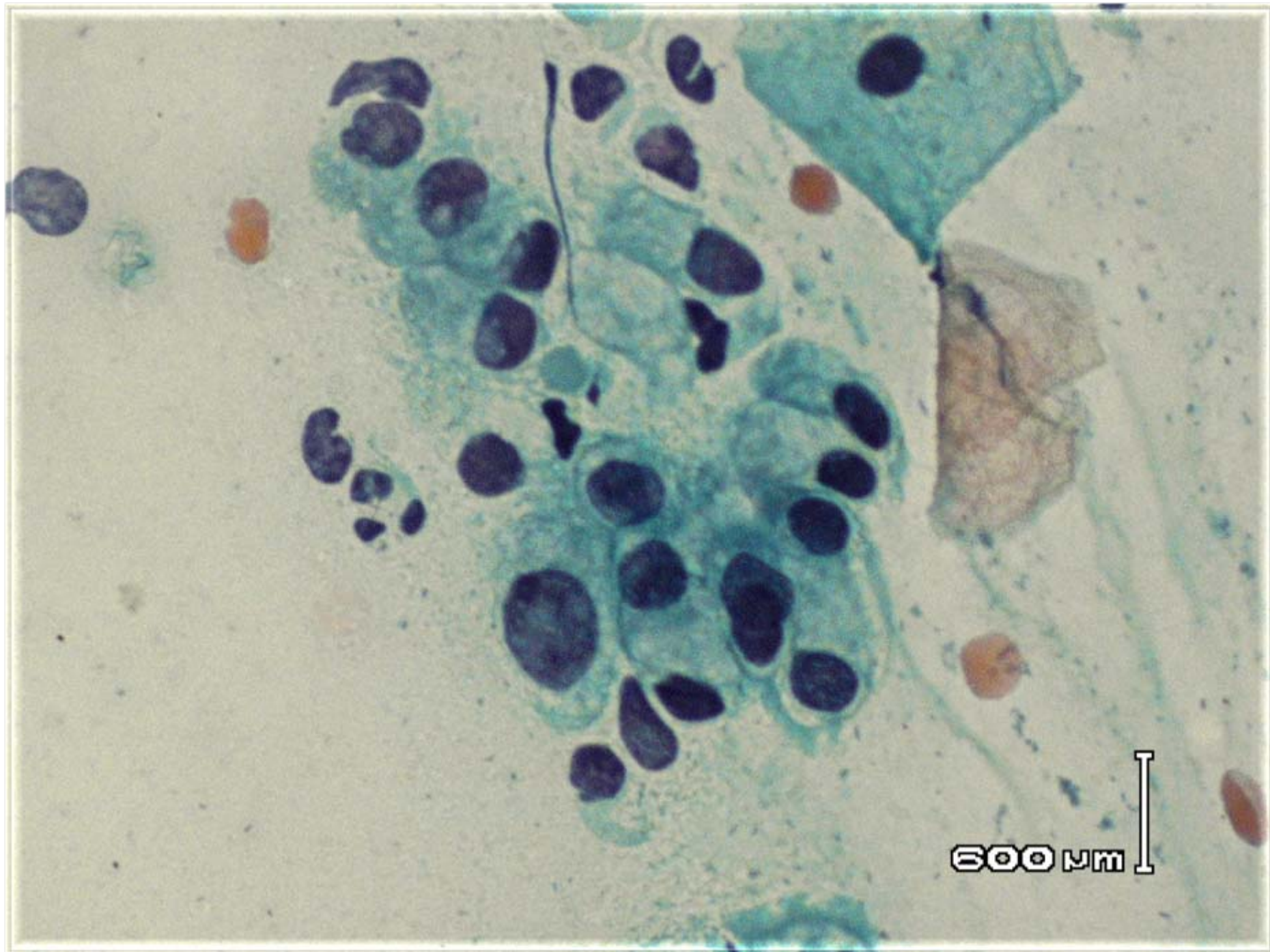
**Citologia anterior: Inflamatório**



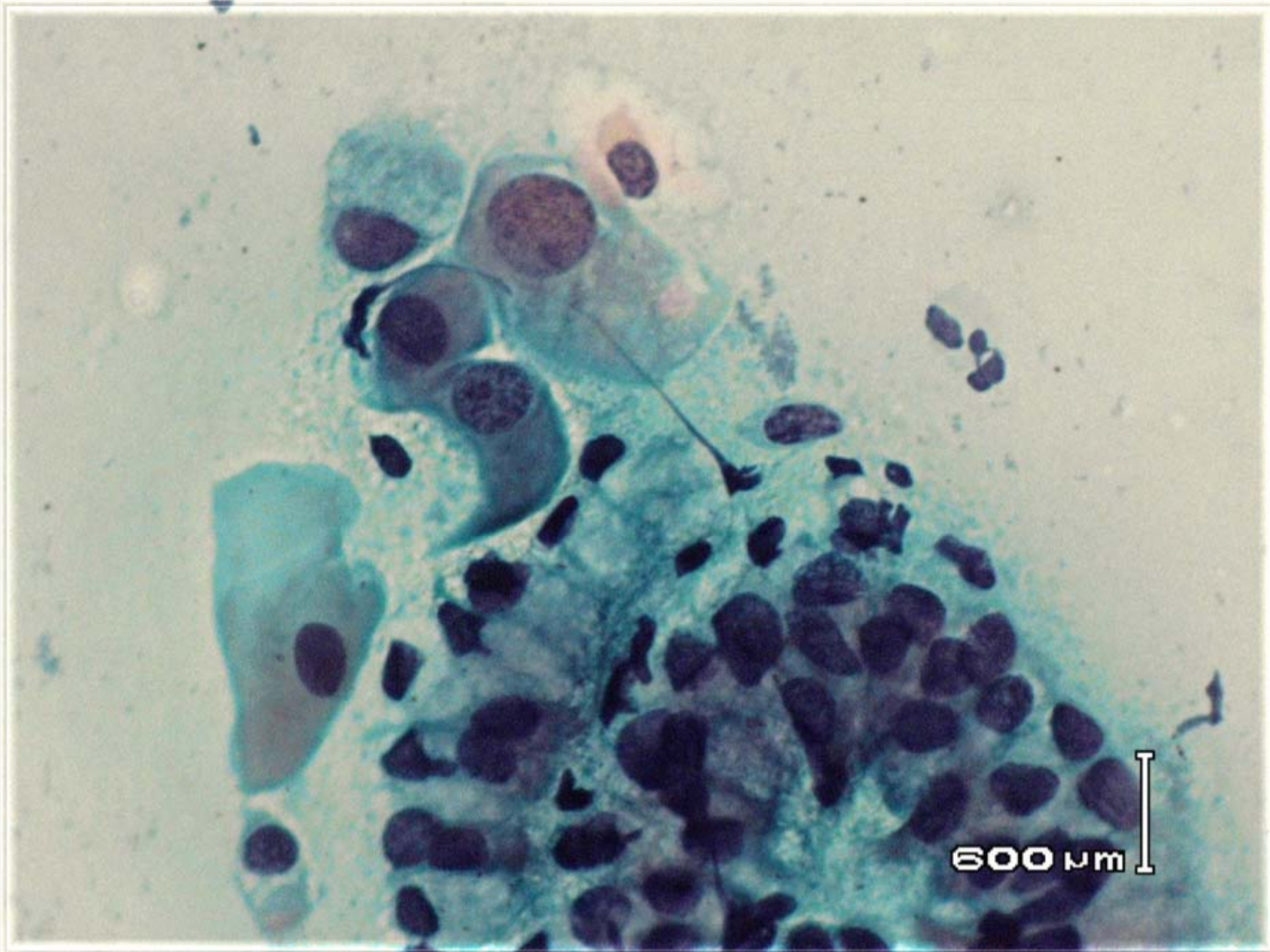
9

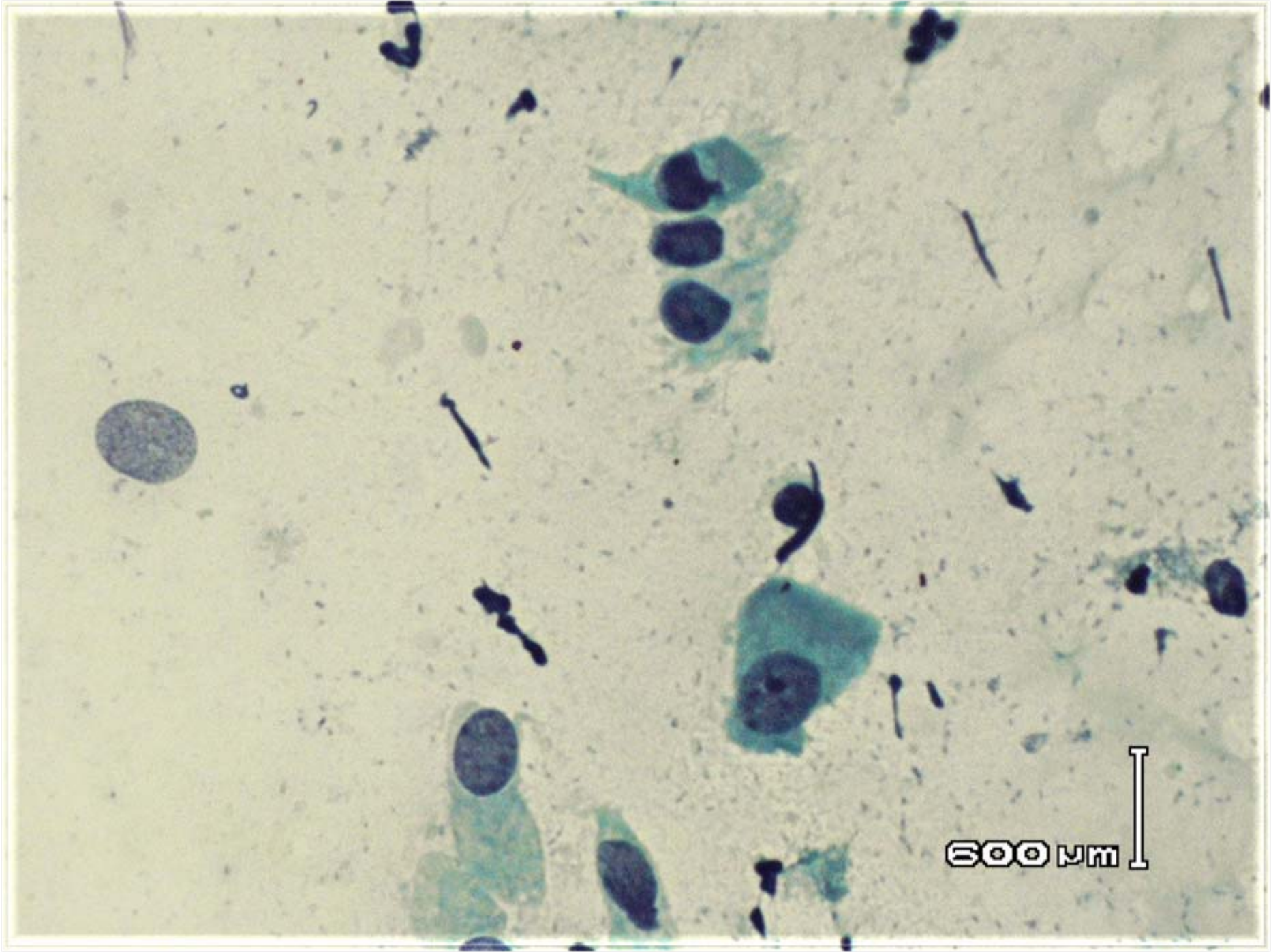
600 μm



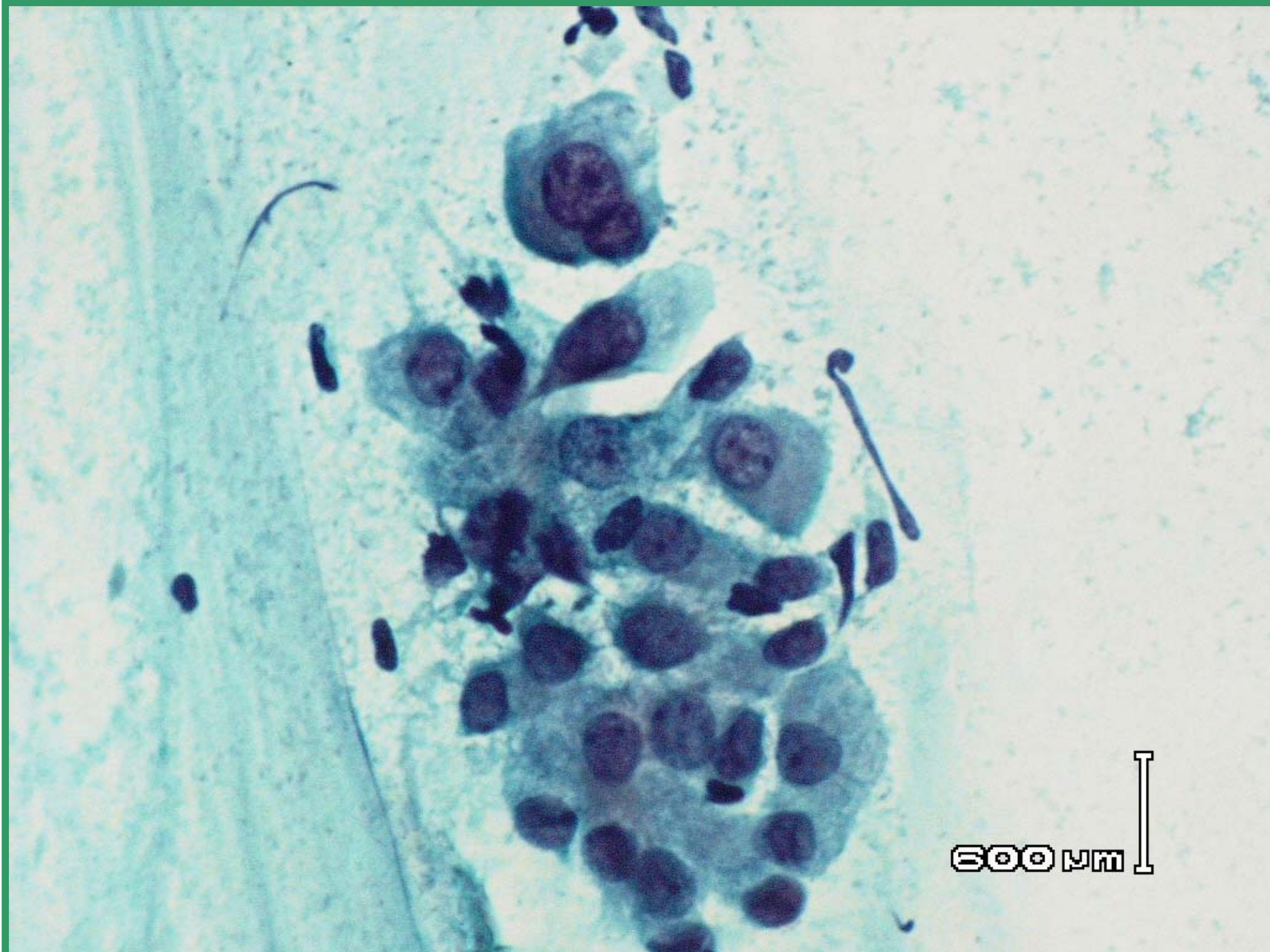


600 μm



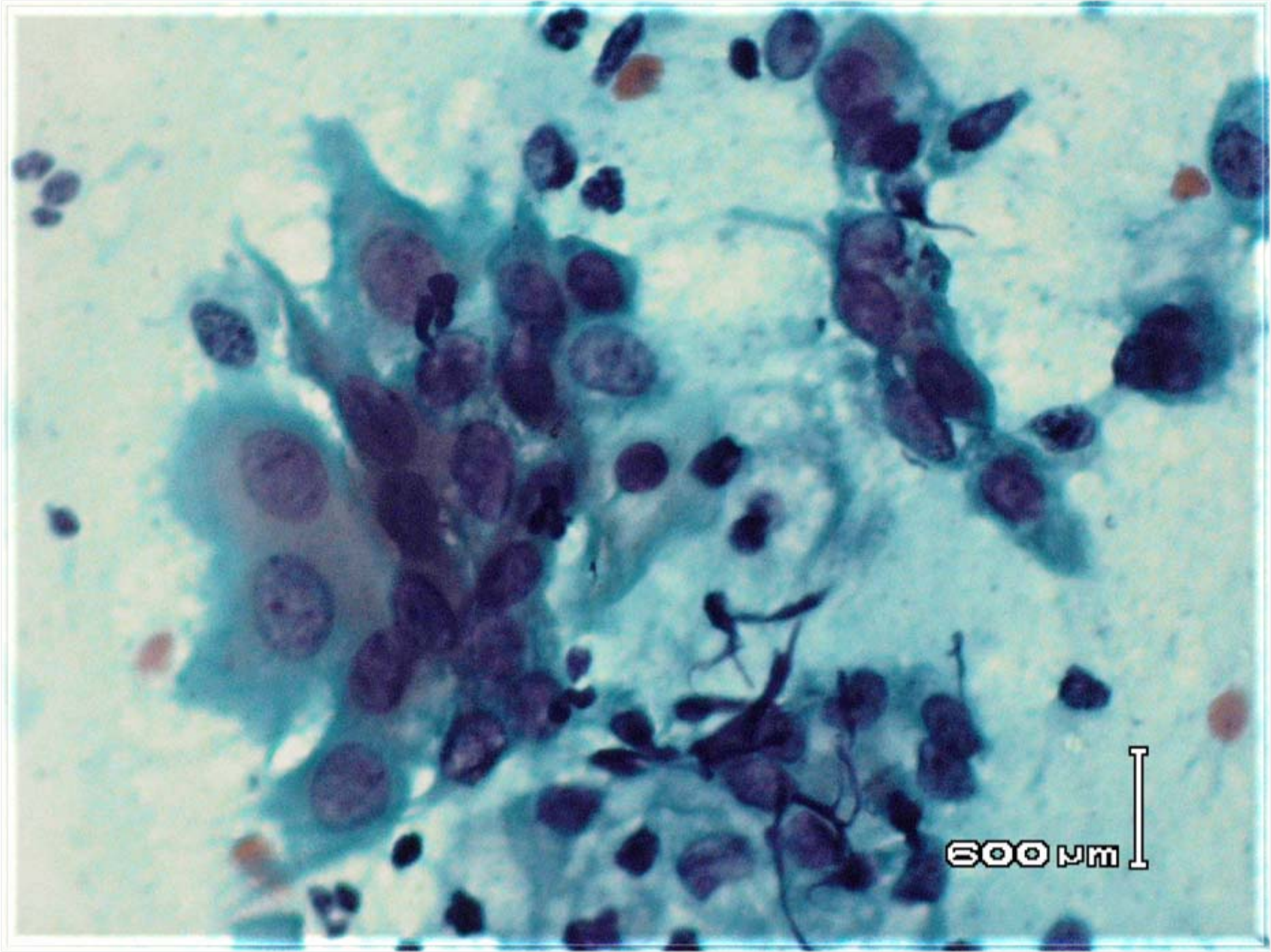


600 μm

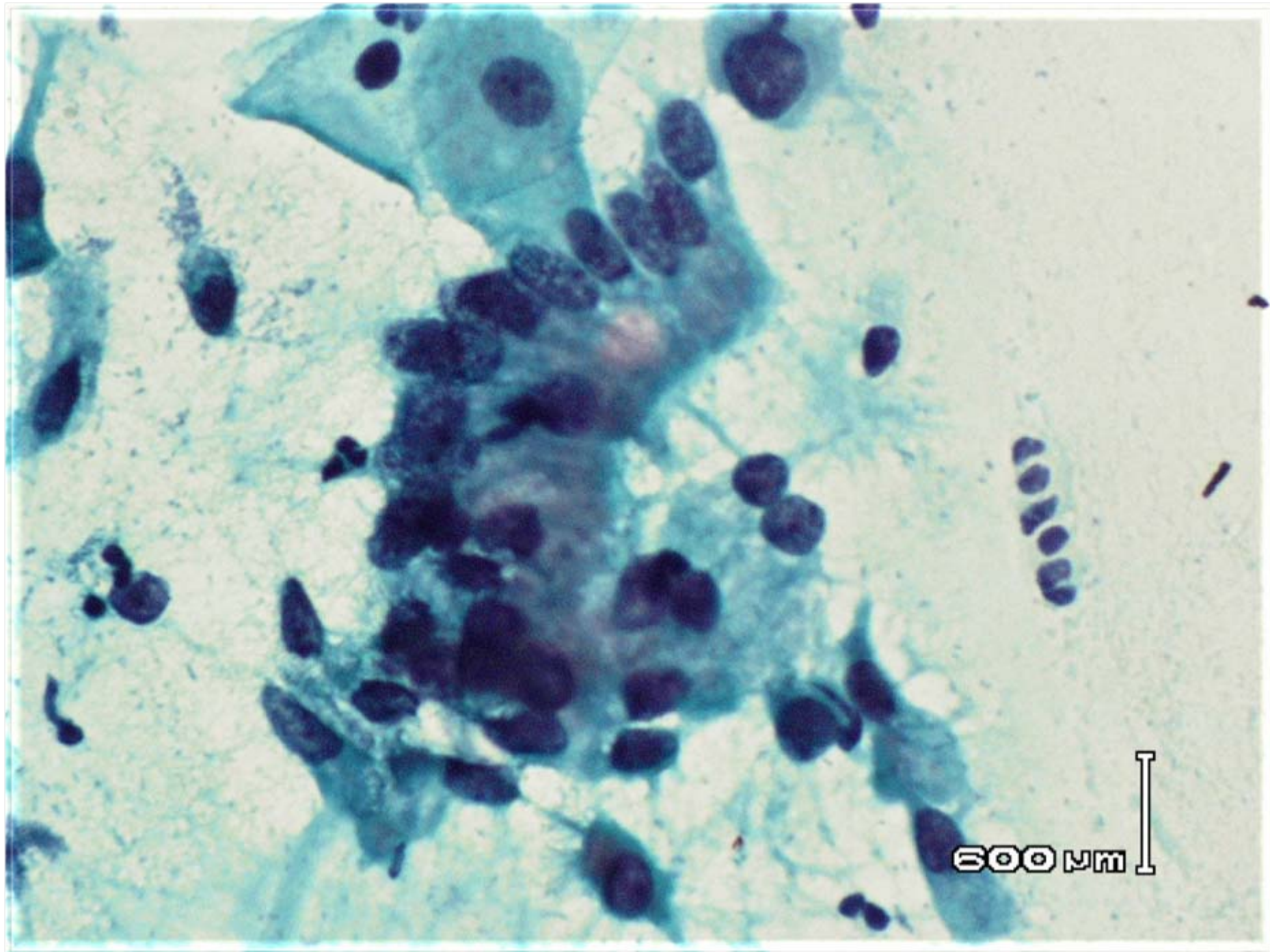


600 nm






600 nm



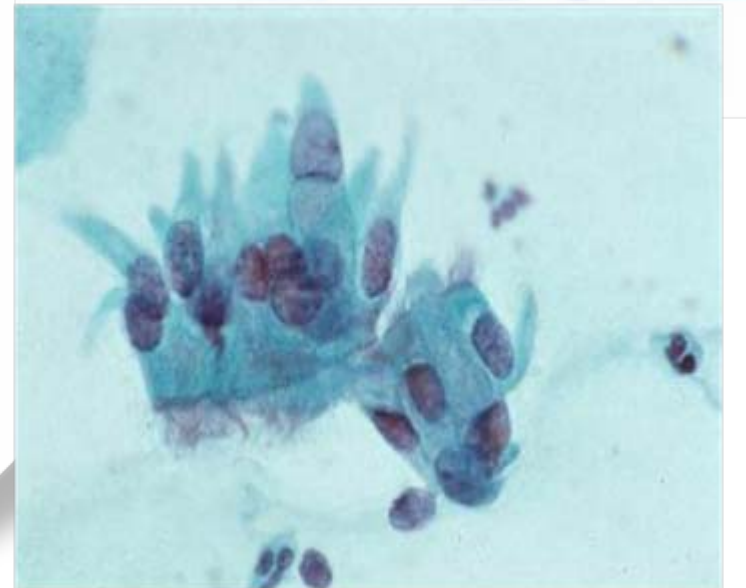
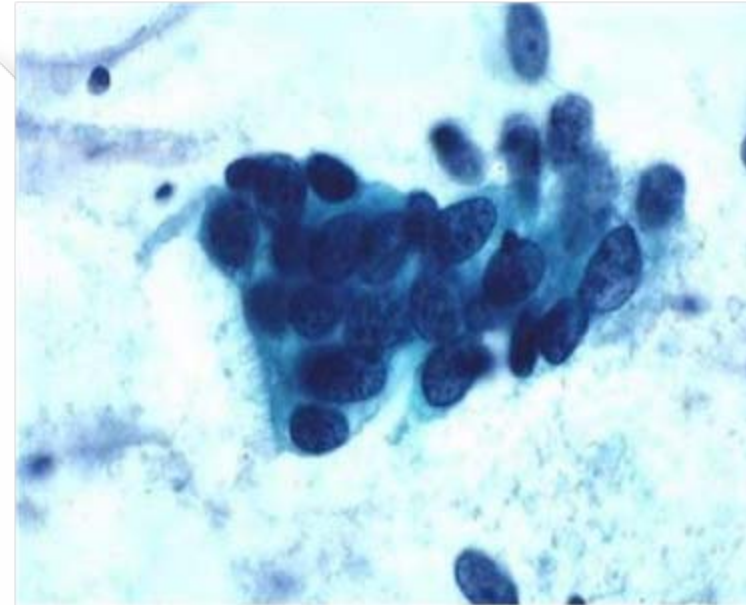
# Diagnóstico Citopatológico

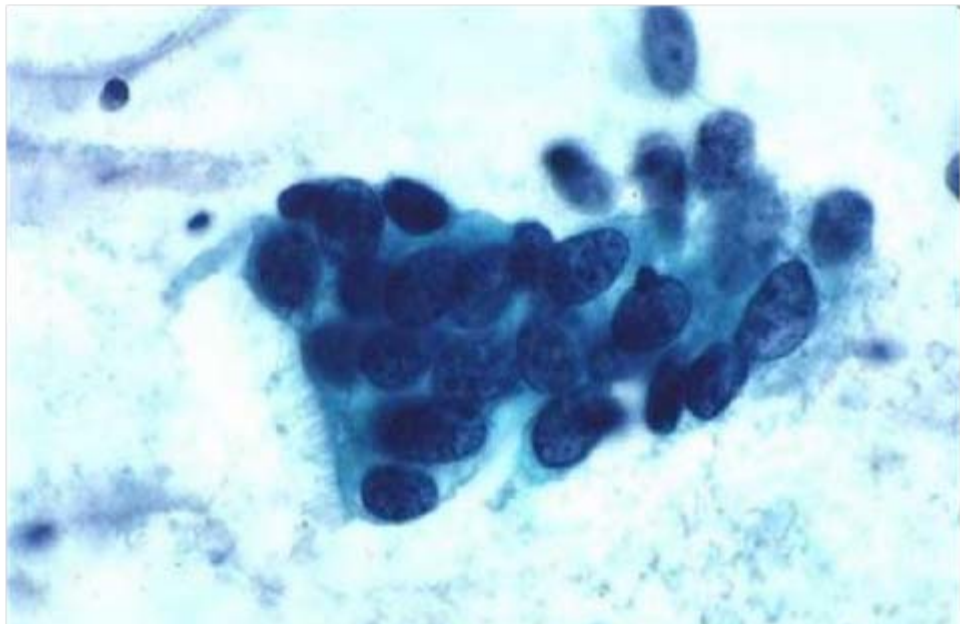
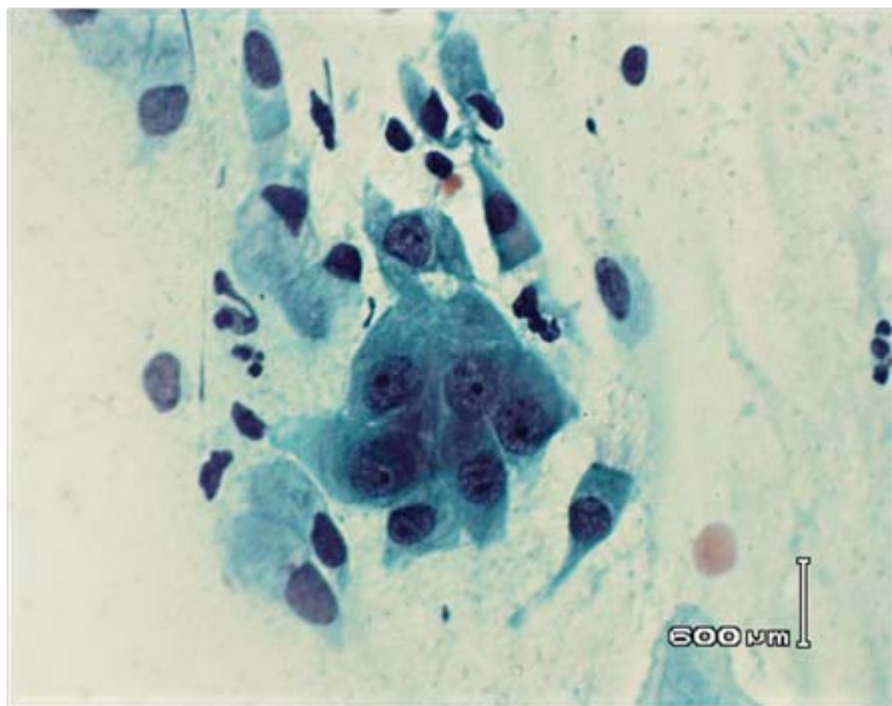
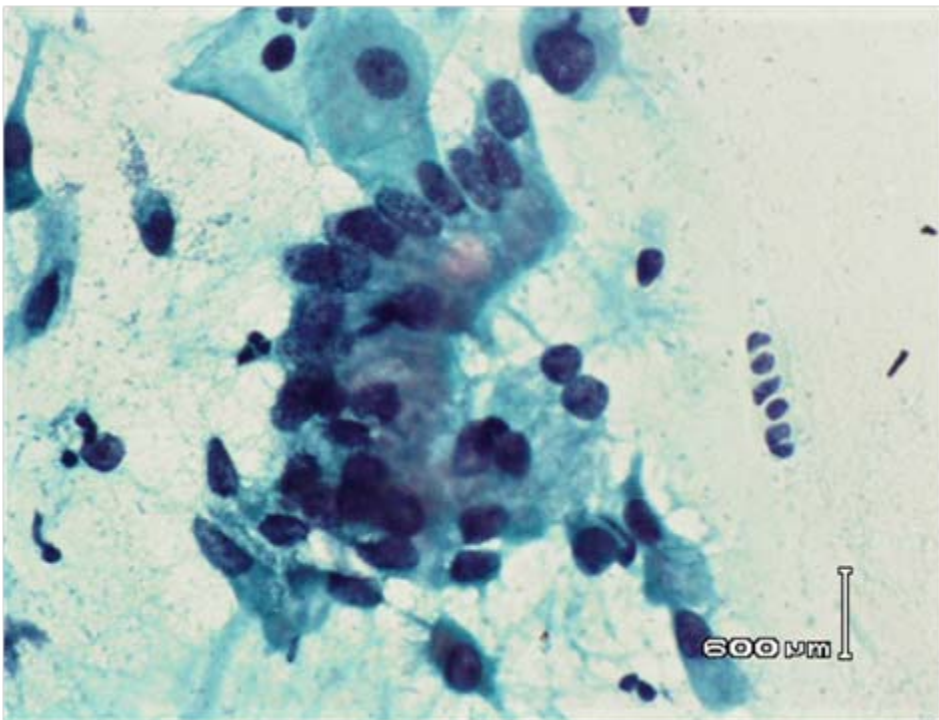


*Inflamatório*  
*Metaplasia tubaria*

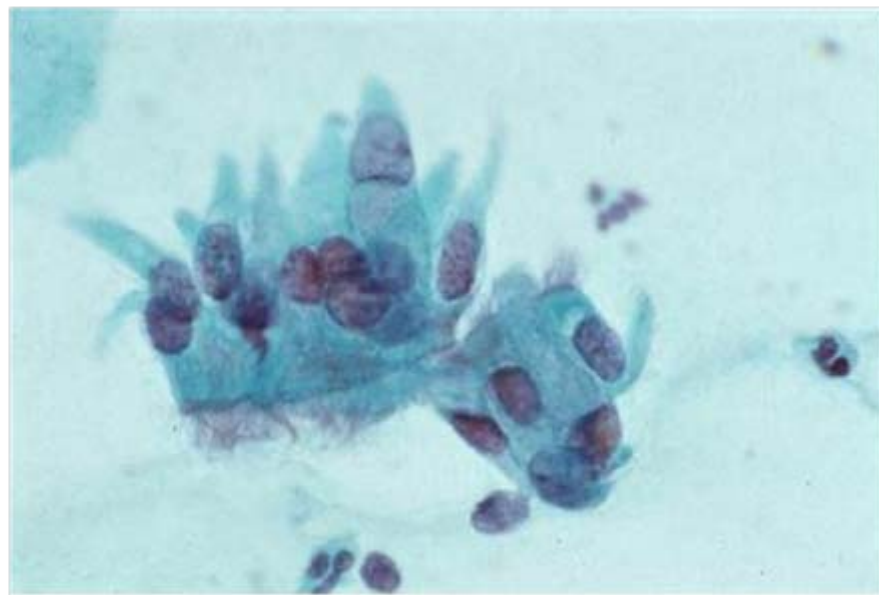
# *Metaplasia Tubaria*

- Células endocervicais  $\Rightarrow$  pequenos grupos ou grupos pseudo-estratificados;
- Núcleo: redondos a ovais e podem estar  $\uparrow$  pleomórficos e hiper Cromáticos;
- RN/C : pode estar elevada;
- Citoplasma pode mostrar vacúolos discretos ou uma alteração caliciforme;
- Presença de cílios e/ou barra terminal é característica, mas células isoladas não são suficientes para estabelecer a designação.





Bethesda



Bethesda

# Obrigado



*Marina Y. S. Maeda*  
**[mysmaeda@gmail.com](mailto:mysmaeda@gmail.com)**